

Intrauterine bone fractures in fetuses with osteogenesis imperfecta: a literature review and a case report

**E.G. Skryabin¹, I.V. Komarova⁵, A.N. Bukseev², I.I. Kukarskaya^{1,5}, M.A. Akselrov^{1,2},
E.B. Khramova¹, S.N. Suprunets^{1,2}, D.A. Popkov⁴**

¹Tyumen State Medical University, Tyumen, Russian Federation

²State budgetary health care institution Tyumen region "Regional clinical hospital № 2", Tyumen, Russian Federation

³State budgetary health care institution Tyumen region "Perinatal Center, Tyumen", Tyumen, Russian Federation

⁴Russian Ilizarov Scientific Center for Restorative Traumatology and Orthopaedics, Kurgan, Russian Federation

The article presents a literature review on intrauterine bone fractures in fetuses suffering from osteogenesis imperfecta. Prenatal ultrasound investigation of the condition is made to identify pathologically changed bone tissue including shortened and deformed limb segments and ribs, bone fractures and callus formation and widened intracranial sutures. Comprehensive clinical, paraclinical and radiological evaluations are produced after the birth to determine treatment strategy. Skeletal fractures in newborns are treated conservatively. With diagnosis of osteogenesis imperfect established medical treatment with bisphosphonates is administered to inhibit osteoclast-mediated bone resorption, facilitate bone mineralization and lower fracture incidence. The case report describes fractures of both femurs and left tibia in a female newborn suffering from osteogenesis imperfecta type III diagnosed *in utero* with ultrasonographic screening. The case presented highlights infant's trauma-focused status, radiological findings and the treatment performed.

Keywords: osteogenesis imperfecta, fetus, intrauterine bone fracture

INTRODUCTION

Different aspects of osteogenesis imperfecta (OI) in children are fully enough described in medical literature [1–4]. Case reports include later types of the disorder mostly developing in the postnatal period [5–7]. There is a paucity of publications on intrauterine bone fractures and

practicing physicians might not be well acquainted with the problem [8–10].

Objective. The purpose of this article is to provide modern medical information on intrauterine bone fractures in fetuses with OI for the greater orthopaedic community and present a case report.

MATERIAL AND METHODS

A search of MEDLINE, PubMed, Ulrich's Periodicals Directory and cyberleninka.ru was conducted for publications on intrauterine bone fractures in fetuses with OI. The depth of literature search was 15 years. A case report of a baby girl with OI presented with intrauterine fractures of both femurs and

left tibia at birth is given as an instance to illustrate the problem. Medical records from women's health center and maternity hospital including ultrasonographic fetal assessment of a 34-year-old lady were used to establish the diagnosis of OI made on clinical examination, radiography and confirmed by genetic testing.

RESULTS

Literature review shows that OI is a genetic disorder characterized by fragile bones, low bone mass, short stature and other signs of bone and connective tissues [11–14]. The main clinical manifestations of the disease include multiple recurrent bone fractures that may lead to physical disability, impaired mobility and performance of ordinary

tasks of everyday living [15, 16]. The number of people born with OI is approximately 0.5–1 in every 10,000 [17, 18]. It is now estimated that the disorder is caused by autosomal dominant mutations in either COL1A1 or COL1A2 genes encoding the chains of type I collagen thus resulting in its quantitative and qualitative reduction and associated musculoskeletal,

Skryabin E.G., Komarova I.V., Bukseev A.N., Kukarskaya I.I., Akselrov M.A., Khramova E.B., Suprunets S.N., Popkov D.A. Intrauterine bone fractures in fetuses with osteogenesis imperfecta: a literature review and a case report. *Genij Ortopedii*. 2018. T. 24. No 4. pp. 521-529. DOI 10.18019/1028-4427-2018-24-4-521-529. (In Russian)

cardiovascular, renal, dental, dermal, ocular and hearing abnormalities [19–24].

D. Sillence et al. [25] formulated the classification currently in use for OI in 1979. The classification is an artificial grouping based on clinical and radiographic features with more types later revised by F.H. Glorieux [26] and F.S. van Dijk et al. [11]. At present, 17 genetic causes of OI [27] and closely related disorders have been identified and it is expected that more will follow with molecular genetic studies [28].

Newborns with OI that sustain intrauterine fractures can be classified as types II and III according to D. Sillence et al. [25] being most severe conditions that are difficult to treat having a poor prognosis [22, 23, 24, 29, 30]. OI type II accounts for 8.4 % of the cases and type III, for 27.4 % according to Russian National Federal Register. OI types I and IV account for 59.0 and 1.7 % of the cases, correspondingly, according to the above Register [31].

C.S. Greeley et al. [32] identified infants and children with IO: type I, 34 %; type II, 2 %, type III, 25 %, type IV, 35 % and unknown type, 4 %. Population sampling of newborns affected with OI indicated to 18.0 [3] to 32.0 % [31] of intrauterine bone fractures with two or more postnatal fractures detected in 10 % of the cases [32].

Bone fractures resulting from intranatal injury are rarely diagnosed in newborns not affected with OI. The published incidence of at-birth fractures is 41 (0.41 %) per 10,000 live births for clavicle [33], 10 (0.01 %) per 10,000 live births for humerus [34] and 1.3 (0.013 %) per 10,000 live births for femur [35].

Although ultrasound is practical to diagnose OI *in utero* it may fail to identify fractures in fetuses [36–39]. According to T.N. Voitovich et al. [40], A.B. Bourgeois et al. [23] OI symptoms can be detected in fetuses by ultrasound screening at 13 to 14 weeks of gestation. M.J. Marion et al. [13] report a 16–20 week screening pregnancy ultrasound to be performed to identify the disease. Review of medical records of 323 children with OI included in the Federal Register of RF indicates to intrauterine fractures diagnosed in 104 cases. A greater number of bone fractures diagnosed *in utero* was recorded in Moscow (n = 8) and Moskovskaya Oblast (n = 7)

from 61 subjects of the Russian Federation. No case of prenatal diagnosis of OI was recorded in 17 (27.8 %) regions of the country [31].

Major ultrasound findings of OI diagnosed *in utero* include shortened limbs and deformed segments of limbs and ribs, callus formation at bone fracture site, poor calcification of cranium and endocranium, macrocephaly and widened intracranial sutures [40, 41]. More postnatal symptoms of OI are observed to develop with growth if an infant survives [1, 14, 27]. Clinical manifestations show aggravated changes in limbs and ribs (100 %), multiplanar deformities of spine and ribcage (80 %), hearing deficiencies (4 %), dentinogenesis imperfecta (24 %), distinct blueness of the sclerae (75 % of clinical observations). Other OI-associated features include visceral herniation, joint hypermobility, aortic and mitral valvular insufficiency due to impaired connective tissue formation [40, 42] and nephrolithiasis [15, 16]. Only 65 % of the children affected by OI are able to walk independently [43].

Differential diagnosis of bone fractures in fetuses with OI is practical for *in utero* bone fractures due to prenatal nerve and muscle diseases [44–46] and osteopetrosis [47]. The differentiation between OI-associated bone fractures sustained by infants in the first days and weeks of life and child abuse with different clinical manifestations of injury to soft tissues of the head, torso and limbs is very important [2, 23].

Pathomorphological studies suggest that OI-associated *in utero* bone fractures occur due to thin (to full resorption) and sparse cortical bone and intraosseous trabeculae [21, 41]. Muscle contraction facilitates fractures of weak bones [13, 24]. Interestingly, the mean consolidation time in prenatal bone fractures is shorter than that in newborns with similar fractures sustained during delivery [48].

There are controversies regarding the mode of delivery for the fetus affected by OI. Several authors support cesarean delivery as one of most effective methods of fracture prevention extracting the baby with caution [24, 49, 50]. There are reports on at-birth fracture rates that do not differ based on whether delivery is by vaginal route or by cesarean

delivery [42, 51]. Confirming the above R. Cubert et al. [52] report that 40 % of infants delivered by cesarean section and 32 % of infants delivered vaginally excluding those with *in utero* fractures had new fractures at birth. C.P. Chen et al. [53] support vaginal delivery in established diagnosis of OI. J. Ruiter-Ligeti et al. [54] made a retrospective cohort studies of 7 287 994 births and encountered 295 (0.004 %) deliveries among women with OI with 75 % of them delivered by cesarean section. Infants born to a woman with OI can have healthy skeleton [55] but there is evidence of infants with OI born to parents who never suffered from any bone pathology [29].

Most publications indicate to a high mortality rate of infants in the first days and weeks of life, type II OI, in particular, termed as perinatal or lethal [25, 29, 30]. Lethal OI may be associated with pulmonary hypoplasia, respiratory insufficiency and extensive intracranial hemorrhage [10, 24].

Treatment of infants with OI is provided by neonatologist physician at the neonatal intensive care unit (NICU) with assistance of related specialties [37, 38]. Symptomatic therapy is indicated for the patients depending on clinical manifestations of OI symptoms [8, 19]. Infants with bone fractures can be immobilized with casts, splints or soft wraps [3, 20, 56, 57]; correcting osteotomies of limb segments and prophylactic reinforcement with metal constructs can be offered for children at an older age [5, 6, 12, 58].

Since 1987 bisphosphonate therapy has been introduced for early application in OI providing a more normal balance between osteoblast-mediated synthesis and osteoclast-mediated bone resorption [22–24, 59, 60]. Bisphosphonate therapy is to be administered in a team approach with geneticist, endocrinologist, radiologist, general surgeon, ophthalmologist, neurologist, dentist and, routinely, orthopedic and trauma surgeon involved [43]. J.J. Sinikumpu et al. [2] advocate intravenous administration of bisphosphonates for newborns shortly after OI is established.

Case report

Our case report presents an infant with OI type III. A baby girl aged 1 day was referred to the NICU unit from

maternity hospital with tentative diagnosis of congenital malformation of locomotor system due to OI.

Life history. The baby was born at full-term pregnancy gravida 4, second emergency spontaneous vaginal delivery, 39 weeks of gestation presented by cranium. Her birth weight was 3740 g, birth length, 54 cm, head circumference, 35.5 cm, ribcage circumference, 32 cm. Apgar score was 7 at 1 minute and 7 at 5 minutes. Pregnancy was complicated by vaginal yeast infection at 9 weeks, asymptomatic bacteriuria at 18 to 23 weeks, placenta dysfunction and vegetative-vascular dystonia of hypotonic type at 23 to 27 weeks and excessive weight gain at 32 to 39 weeks.

Medical history. Fetal ultrasound imaging of 34–35-weeks' gestation showed signs of hypomineralized skull, head deformity with probe pressure, shortening of long bones by 6½ weeks, varus deformity of tibiae, fractures of both femurs (**Fig. 1, a, b**) and the left tibia (**Fig. 1, c**), and hypoplastic nasal bone.

The findings indicated to fetal ultrasound symptoms of OI. The previous fetal ultrasound examinations performed at 12-to-13-week and 20-to-21-week gestations showed no bone abnormalities. Parents and the family reported no history of skeletal systemic diseases.

Objective status. General condition of the baby was rated as severe due to congenital malformation of locomotor apparatus. Nutrition was satisfactory. Physical development was appropriate for gestational age. Condition and functioning of organs and systems but neurological status matched baby's age.

Local status of musculoskeletal system showed adequate head position without fixed deformities and pathologies. Good alignment of upper limbs with sufficient passive range of motion in major joints. Pathological mobility was palpated neither in the clavicle nor in the upper limb segments. Ribcage halves were symmetrical and not deformed. The spine axis matched according to age. Femoral alignment was visually good and tibiae were in varus. No pathological mobility was observed palpating femurs and pathological mobility noted at palpation in mid third of the left tibia without evident crepitation of bone fragments. No fixed deformities and pathologies observed in the feet.

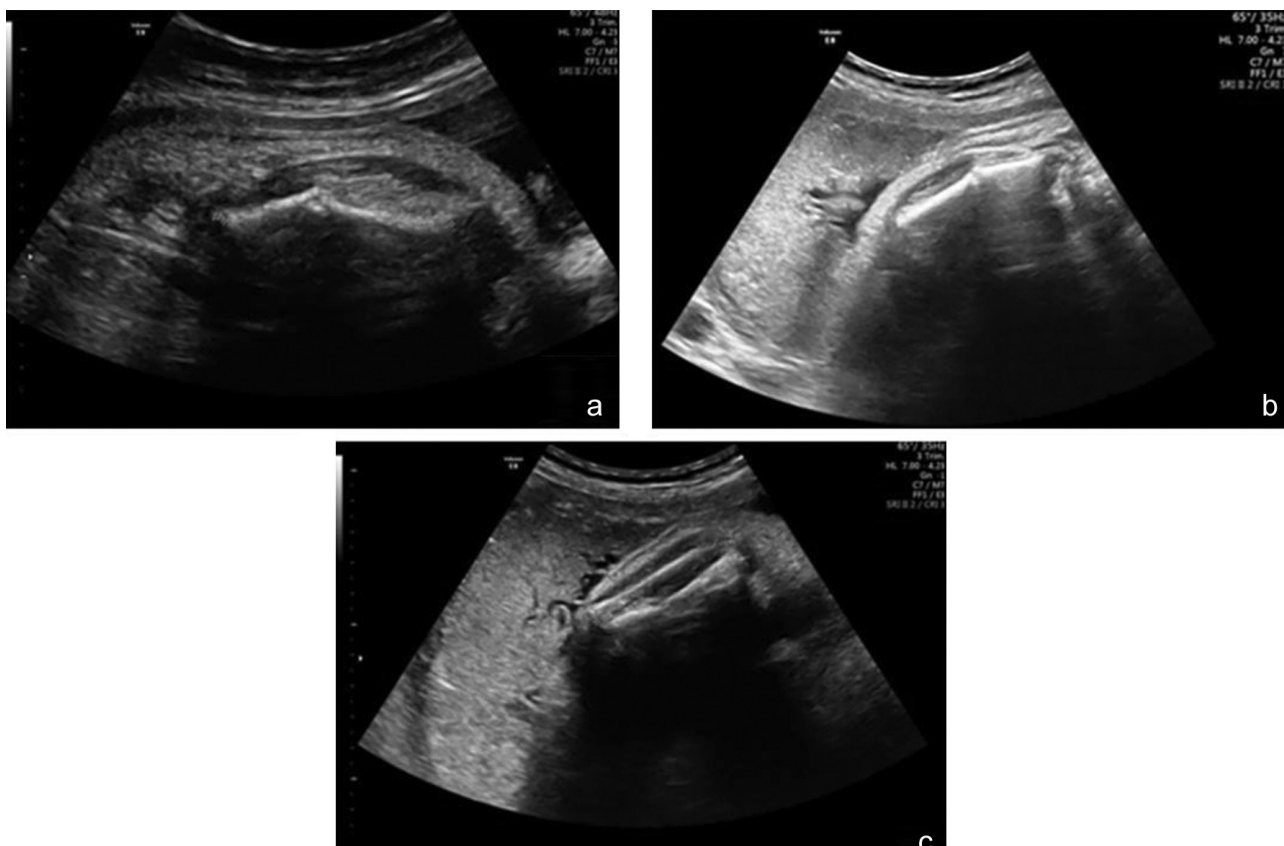

Fig. 1 Fetal ultrasound images showing *in utero* fractures of the right (a), left (b) femurs and left tibia (c)

No traumatic injuries were seen in the radiographs of upper limbs, clavicles and ribcage. Radiographs of lower limbs showed consolidating fractures of the right and left femurs in the middle third and transverse fracture of the right tibia in the middle third (**Fig. 2**). General clinical, biochemical and functional examinations of the newborn were performed in dynamics including consultations from orthopaedic and trauma surgeon, endocrinologist, geneticist, neurologist and general surgeon. Clinical diagnosis made on the basis of medical history,

clinical diagnostic tests, examinations of related specialties included congenital malformation of locomotor apparatus: OI type III, consolidation fracture of the right and left femurs, and the left tibia, cerebral ischemia grade II, acute symptomatic cramps, patent arterial duct, patent foramen ovale, cephalohematoma in the left parietal bone, positional plagiocephaly.

Femurs and tibiae were immobilized with posterior plaster cast and pelvic support after radiological assessment of traumatic injuries (**Fig. 3**).

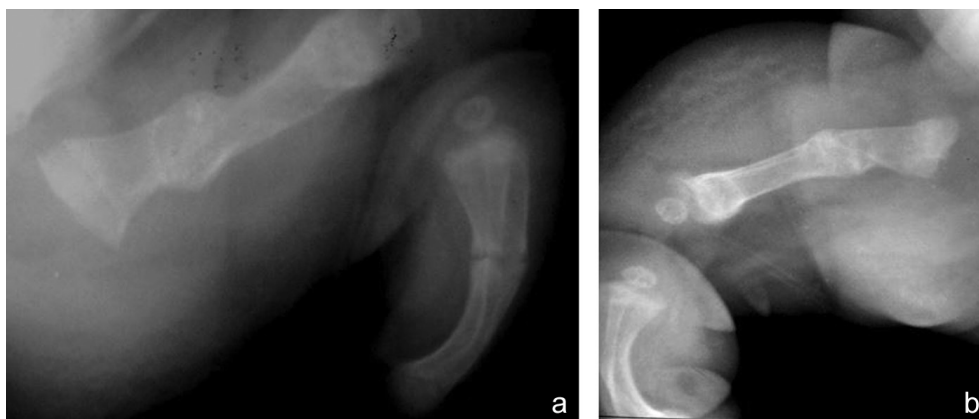


Fig. 2 Radiographs of lower limbs of a one-day-old newborn Sh. showing (a) consolidating fracture of the right femur and varus deformity of the right tibia; (b) consolidating fracture of the left femur and left tibia

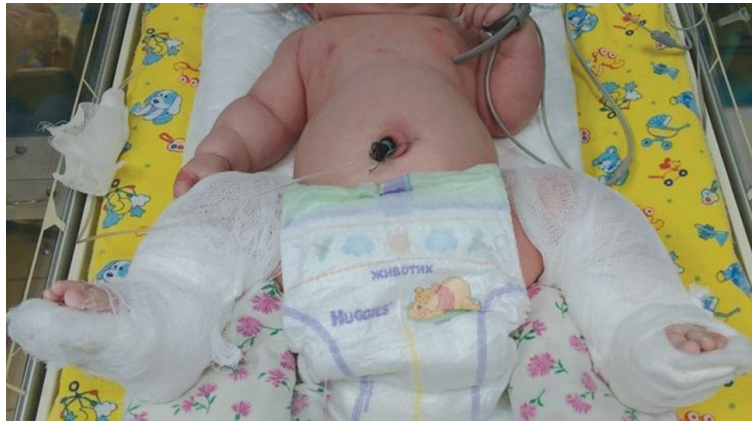

Fig. 3 Photograph of the 2-day-old baby girl showing lower limbs fixed with plaster cast

Infusion, anesthesia, antibacterial, anticoagulation and calcium-rich therapy was provided for the baby girl at the NICU. Bisphosphonates (Rezoklastin FS (zoledronic acid) at the dose of 0.05 mg/kg) were administered by interdisciplinary team's decision. Neither arterial blood pressure measurement with the cuff nor baby weighing were performed to prevent acute bone fractures of upper limbs. The baby girl

was treated in an open NICU system using corrective mattress. Both mother and baby were discharged from the NICU after 16 days with the care for NICU graduate discussed in details. Immobilization of lower limbs with plaster cast lasted throughout the admission at the NICU and terminated before the discharge. Meanwhile no clinical symptoms of acute clavicle, rib, long bone fractures were recorded.

DISCUSSION

Literature review shows that prenatal diagnosis of OI is based on ultrasound findings of bone pathology, primarily in skull bones and limb segments [36, 38]. Pregnant women affected by OI should be closely monitored to assess fetal well-being and detect pregnancy related complications. There is no identifiable relationship between affected pregnancy and fetus with OI. OI can be suspected in a fetus of an unaffected mother when ultrasound shows shortened and deformed segments of limbs and ribs, acute fractures or bone callus in long bones and insufficient skull mineralization [2, 13, 23, 40]. Pregnant women at risk of fetal OI should be made aware of various complications that can be associated with OI and pregnancy. Discussion would include the availability of various prenatal diagnosis techniques to direct the remainder of the prenatal care including accuracy of the diagnosis, severity of the disorder, prognosis for survival and development, and mode of delivery. Consultation with orthopaedic and trauma surgeon, neurologist are arranged for the newborn shortly at birth and the baby is referred to NICU from maternity

hospital to facilitate further diagnostic tests, assessment (primarily radiological) and involvement of other relevant professionals to identify treatment tactics. If a bone fracture is detected radiologically it is managed with immobilization using plaster cast for acute cases [2, 24]. The possibility with preventive neonatal reinforcement of long bones in the manner applied for older children [6, 7] is not discussed in the literature.

The case presented is characterized by late ultrasound diagnosis of bone softening and fractures. Literature review shows that bone abnormalities of OI types II and III can be identified with ultrasonography at the end of the first trimester or early in the second trimester and radiograph of the fetus is used to confirm the diagnosis [22]. *In utero* bone fractures were not timely detected in the case reported but identified only at 34-35-week gestation. Severity of the condition required appropriate treatment that included immobilization of broken bone with plaster cast, drug therapy using bisphosphonate (Rezoklastin FS) and measures undertaken to prevent skeletal fractures.

CONCLUSION

Review of the current medical literature shows that OI related issues of diagnosis and prognosis have been largely resolved in recent years. Ultrasonography is acknowledged as a reliable diagnostic modality for the prenatal diagnosis of OI. Because all genetic causes for OI have not yet been identified pathogenetic mechanisms of the debilitating disorder are often difficult to be managed. But cautious optimism of some reputable researchers brings hope of a breakthrough in this very important aspect [4, 13, 19, 20, 28].

REFERENCES

1. Khan M.K., Hossain M.B. A case of brittle bone disease. *Mymensingh Med. J.*, 2004, vol. 13, no. 2, pp.199-200.
2. Sinikumpu J.J., Ojaniemi M., Lehenkari P., Serlo W. Severe osteogenesis imperfecta Type-III and its challenging treatment in newborn and preschool children. A systematic review. *Injury*, 2015, vol. 46, no. 8, pp. 1440-1446. DOI: 10.1016/j.injury.2015.04.021.
3. Yimgang D.P., Brizola E., Shapiro J.R., Health outcomes of neonates with osteogenesis imperfecta: a cross-sectional study. *J. Matern. Fetal Neonatal Med.*, 2016, vol. 29, no. 23, pp. 3889-3893. DOI: 10.3109/14767058.2016.1151870.
4. Bateman J.F., Chan D., Mascara T., Rogers J.G., Cole W.G. Collagen defects in lethal perinatal osteogenesis imperfecta. *Biochem. J.*, 1986, vol. 240, no. 3, pp. 699-708.
5. Popkov A.V., Popkov D.A., Shutov R.B., comp. *Operativnoe lechenie detei s nesovershennym osteogenezom (Q 78.0): klinicheskie rekomendatsii [Surgical treatment of children with osteogenesis imperfecta (Q 78.0): technique manual]. Obshcheros. obshchestv. organizatsiia; Assots. travmatologov-ortopedov (ATOR) [All-Russian Public Organization, Association of Traumatologists-orthopedists (ATO)]. Kurgan, 2013, 16 p. (in Russian)*
6. Mingazov E.R., Chibirov G.M., Popkov D.A. Khirurgicheskie metody lecheniia deformatsii konechnosti u detei s nesovershennym osteogenezom (obzor literatury) [Surgical methods for treatment of limb deformities in children with osteogenesis imperfecta (A review of the literature)]. *Genij Ortopedii*, 2016, no. 2, pp. 97-103. DOI: 10.18019/1028-4427-2016-2-97-103. (in Russian)
7. Pashenko A. Results of application of intramedullary telescopic fixators in the treatment of long bone deformities of limbs in children with osteogenesis imperfecta. *Orthopaedics, Traumatology and Prosthetics*, 2016, no. 3, pp. 66-72. DOI: 10.15674/0030-59872016366-72.
8. Kostik M.M., Kalashnikova O.V., Galustian A.N., Shchepiagina L.A., Larionova V.I. Diagnostika i lechenie nesovershennogo osteogeneza [Diagnosis and treatment of osteogenesis imperfecta]. *Lechenie i Profilaktika*, 2011, no. 1, pp. 65-69. (in Russian)
9. Jakubowska-Pietkewicz E., Rusińska A., Michałus I., Chlebna-Sokół D. Brittle bone disease type III in neonates – own experience. *Przegl. Lek.*, 2012, vol. 69, no. 4, pp. 139-142.
10. Himakhun W., Rojnuangnit K., Prachukthum S. Perinatal lethal osteogenesis imperfecta in a Thai newborn: the autopsy and histopathological findings. *J. Med. Assoc. Thai.*, 2012, vol. 95, no. Suppl. 1, P. S190-S194.
11. Van Dijk F.S., Pals G., van Rijn R.R., Nikkels P.G., Cobben J.M. Classification of Osteogenesis imperfecta revisited. *Eur. J. Med. Genet.*, 2010, vol. 53, no. 1, pp.1-5. DOI: 10.1016/j.ejmg.2009.10.007.
12. Popkov D.A., Leonchuk S.S., Popkov A.V., Mingazov E.R., comp. *Nesovershennyi osteogenez: klinicheskie rekomendatsii [Osteogenesis imperfecta: clinical guidelines]. Kurgan, 2016. (in Russian) Available at: https://medi.ru/klinicheskie-rekomendatsii/nesovershennyi-osteogenez_14106/#part_13. (accessed 15.10.17).*
13. Marion M.J., Gannon F.H., Fallon M.D., Mennuti M.T., Lodato R.F., Kaplan F.S. Skeletal dysplasia in perinatal lethal osteogenesis imperfecta. A complex disorder of endochondral and intramembranous ossification. *Clin. Orthop. Relat. Res.*, 1993, no. 293, pp.327-337.
14. Binder H. Rehabilitation of infants with osteogenesis imperfecta. *Connect. Tissue Res.*, 1995, vol. 31, no. 4, pp. S37-S39.
15. Povorozniuk V.V., Dedukh N.V., Grechanina E.Ia., Balatskaia N.I., Vaida V.M. Nesovershennyi osteogenez: patogenez, klassifikatsiia, klinicheskaia kartina, lechenie [Osteogenesis imperfecta: pathogenesis, classification, clinical picture, treatment]. *Problemi Osteologii*, 2009, vol. 12, no. 4, pp. 38-48. (in Russian) Available at: http://nbuv.gov.ua/UJRN/prost_2009_12_4_6. (accessed 27.06.18)
16. Viktorova I.A., Konshu N.V., Ivanova D.S. Nesovershennyi osteogenez: polimorfizm klinicheskikh proiavlenii i taktika lecheniia [Osteogenesis imperfecta: polymorphism of clinical manifestations and tactics of treatment]. *Arkhiv Vnutrennei Meditsiny*, 2015, no. 2 (22), pp. 69-73. (in Russian)
17. Folkestad L., Hald J.D., Ersbøl A.K., Gram J., Hermann A.P., Langdahl B., Abrahamsen B., Brixen K. Fracture Rates and Fracture Sites in Patients With Osteogenesis Imperfecta: A Nationwide Register-Based Cohort Study. *J. Bone Miner. Res.*, 2017, vol. 32, no. 1, pp. 125-134. DOI: 10.1002/jbmr.2920.
18. Michell C., Patel V., Amirfeyz R., Gargan M. Osteogenesis imperfecta. *Curr. Orthop.*, 2007, vol. 21, no. 3, pp. 236-241. DOI: 10.1016/j.cuor.2007.04.003.

19. Takagi M., Shinohara H., Narumi S., Nishimura G., Hasegawa Y., Hasegawa T. Severe osteogenesis imperfecta caused by double glycine substitutions near the amino-terminal triple helical region in COL1A2. *Am. J. Med. Genet. A*, 2015, vol. 167, no. 7, pp. 1627-1631. DOI: 10.1002/ajmg.a.37051.
20. Cheung M.S., Glorieux F.H. Osteogenesis Imperfecta: update on presentation and management. *Rev. Endocr. Metab. Disord.*, 2008, vol. 9, no. 2, pp. 153-160. DOI: 10.1007/s11154-008-9074-4.
21. Cole W.G., Patterson E., Bonadio J., Campbell P.E., Fortune D.W. The clinicopathological features of three babies with osteogenesis imperfecta resulting from the substitution of glycine by valine in the pro alpha 1 (I) chain of type I procollagen. *J. Med. Genet.*, 1992, vol. 29, no. 2, pp. 112-118.
22. Baalbaky I., Manouvrier S., Dufour P., Devismes L., Delzenne A., Boute O., Puech F. Prenatal diagnosis of osteogenesis imperfecta. Two cases. *J. Gynecol. Obstet. Biol. Reprod.*, 1998, vol. 27, no. 1, pp. 44-51.
23. Bregou Bourgeois A., Aubry-Rozier B., Bonafé L., Laurent-Applegate L., Pioletti D.P., Zambelli P.Y. Osteogenesis imperfecta: from diagnosis and multidisciplinary treatment to future perspectives. *Swiss Med. Wkly*, 2016, vol. 146, pp. w14322. DOI: 10.4414/smw.2016.14322.
24. Shaker J.L., Albert C., Fritz J., Harris G. Recent developments in osteogenesis imperfecta. *F1000Res*, 2015, vol. 4, F 1000 Faculty Rev., pp. 681. DOI: 10.12688/f1000research.6398.1.
25. Sillence D.O., Senn A., Danks D.M. Genetic heterogeneity in osteogenesis imperfecta. *J. Med. Genet.*, 1979, vol. 16, no. 2, pp. 101-116.
26. Glorieux F.H. Osteogenesis imperfecta. *Best Pract. Res. Clin. Rheumatol.*, 2008, vol. 22, no. 1, pp. 85-100. DOI: 10.1016/j.berh.2007.12.012.
27. Bishop N. Characterising and treating osteogenesis imperfecta. *Early Hum. Dev.*, 2010, vol. 86, no. 11, pp. 743-746. DOI: 10.1016/j.earlhumdev.2010.08.002.
28. Van Dijk F.S., Sillence D.O. Osteogenesis imperfecta: clinical diagnosis, nomenclature and severity assessment. *Am. J. Med. Genet. A*, 2014, vol. 164A, no. 6, pp. 1470-1481. DOI: 10.1002/ajmg.a.36545.
29. Moyon G., Nkoua J.L., Pongui M., Mafouta A.M., Nzingoula S. Lethal osteogenesis imperfecta in a Congolese newborn infant. *Arch. Fr. Pediatr.*, 1993, vol. 50, no. 10, pp. 891-895.
30. Ayadi I.D., Hamida E.B., Rebeh R.B., Chaouachi S., Marrakchi Z. Perinatal lethal type II osteogenesis imperfecta: a case report. *Pan Afr. Med. J.*, 2015, vol. 21, pp. 11. DOI: 10.11604/pamy.2015.21.11.6834.
31. Iakhiaeva G.T., Namazova-Baranova L.S., Margieva T.V., Chumakova O.V. Nesovershennyi osteogenez u detei v Rossiiskoi Federatsii: rezultaty audita federalnogo registra [Osteogenesis imperfecta in children of the Russian Federation: results of the audit of the Federal Register]. *Pediatricheskaja Farmakologija*, 2016, vol. 13, no. 1, pp. 44-48. DOI: 10.15690/pf.v13i1/1514. (in Russian)
32. Greeley C.S., Donaruma-Kwoh M., Vettimattam M., Lobo C., Williard C., Mazur L. Fractures at diagnosis in infants and children with osteogenesis imperfecta. *J. Pediatr. Orthop.*, 2013, vol. 33, no. 1, pp. 32-36. DOI: 10.1097/BPO.0b013e318279c55d.
33. Ahn E.S., Jung M.S., Lee Y.K., Ko S.Y., Shin S.M., Hahn M.H. Neonatal clavicular fracture: recent 10 year study. *Pediatr. Int.*, 2015, vol. 57, no. 1, pp. 60-63. DOI: 10.1111/ped.12497.
34. Mane P.P., Challawar N.S., Shah H. Late presented case of distal humerus epiphyseal separation in a newborn. *BMJ Case Rep.*, 2016, vol. 2016, pp. bcr2016215296. DOI: 10.1136/bsr-2016-215296.
35. Morris S., Cassidy N., Stephens M., McCormack D., McManus F. Birth-associated femoral fractures: incidence and outcome. *J. Pediatr. Orthop.*, 2002, vol. 22, no. 1, pp. 27-30.
36. Tennstedt C., Bartho S., Bollmann R., Schwenke A., Nitz I., Rothe K. Osteochondrodysplasias. Prenatal diagnosis and pathological-anatomic findings. *Zentralbl. Pathol.*, 1993, vol. 139, no. 1, pp. 71-80.
37. Hackley L., Merritt L. Osteogenesis imperfecta in the neonate. *Adv. Neonatal Care*, 2008, vol. 8, no. 1, pp. 21-30. DOI: 10.1097/01.ANC.0000311013.71510.41.
38. Chalubinski K., Schaller A. Prenatal diagnosis of osteogenesis imperfecta. Report of a case classified as the classical Ekman Lobstein type. *Ultraschall. Med.*, 1994, vol. 15, no. 1, pp. 38-42. DOI: 10.1055/s-2007-1004003.
39. Aylsworth A.S., Seeds J.W., Guilford W.B., Burns C.B., Washburn D.B. Prenatal diagnosis of a severe deforming type of osteogenesis imperfecta. *Am. J. Med. Genet.*, 1984, vol. 19, no. 4, pp. 707-714. DOI: 10.1002/ajmg.1320190410.
40. Voitovich T.N., Baranaeva E.A., Bezler Zh.A., Chanchikova M.V. Nesovershennyi osteogenez [Osteogenesis imperfecta]. *Meditsinskii Zhurnal*, 2009, no. 2 (28), pp. 138-140. (in Russian)
41. Limarenko M.P., Smirnova T.V., Dubovaia A.V., Neborak E.N. Nesovershennyi osteogenez v praktike pediatra [Osteogenesis imperfecta in a pediatrician's practice]. *Sovremennaja Pediatriia*, 2008, no. 2 (19), pp. 92-95. (in Russian)
42. Mravian S.R., Shuginin I.O., Novikova S.V., Upriamova E.Iu., Bocharova I.I., Zhuchenko L.A. Nesovershennyi osteogenez i beremennost: problemy, narastaiushchie k rodam [Osteogenesis imperfecta and pregnancy: problems growing to childbirth]. *Almanakh Klinicheskoi Meditsiny*, 2015, no. 37, pp. 47-51. (in Russian)
43. Iakhiaeva G.T., Namazova-Baranova L.S., Margieva T.V. Novye aspekty geneticheskoi osnovy, klassifikatsii i lecheniia nesovershennogo osteogeneza: literaturnyi obzor [New aspects of genetic basis, classification and treatment of osteogenesis

- imperfecta: review of the literature]. *Pediatricheskaja Farmakologija*, 2015, vol. 12, no. 5, pp. 579-588. DOI 10.15690/pf.v12i5.1461. (in Russian)
44. Dadali E.L., Sharkova I.V., Bessonova L.A., Zabnenkova V.V., Poliakov A.V. Sluchai diagnostiki proksimalnoi amiotrofii s vrozhdennymi perelomami [The case of diagnosing proximal amyotrophy with congenital fractures]. *Nervno-myshechnye Bolezni*, 2012, no. 3, pp. 67-70. (in Russian)
45. Courtens W., Johansson A.B., Dachy B., Avni F., Telerman-Toppet N., Scheffer H. Infantile spinal muscular atrophy variant with congenital fractures in a female neonate: evidence for autosomal recessive inheritance. *J. Med. Genet.*, 2002, vol. 39, no. 1, pp. 74-77.
46. Abbott M., Jain M., Pferdehirt R., Chen Y., Tran A., Duz M.B., Seven M., Gibbs R.A., Muzny D., Lee B., Marom R., Burrage L.C. Neonatal fractures as a presenting feature of LMOD3-associated congenital myopathy. *Am. J. Med. Genet. A*, 2017, vol. 173, no. 10, pp. 2789-2794. DOI: 10.1002/ajmg.a.38383.
47. El Khazen N., Faverly D., Vamos E., Van Regemorter N., Flament-Durand J., Carton B., Cremer-Perlmutter N. Lethal osteopetrosis with multiple fractures in utero. *Am. J. Med. Genet.*, 1986, vol. 23, no. 3, pp. 811-819. DOI: 10.1002/ajmg.1320230308.
48. Hosokawa T., Yamada Y., Sato Y., Tanami Y., Oguma E. Subperiosteal new bone and callus formations in neonates with femoral shaft fracture at birth. *Emerg. Radiol.*, 2017, vol. 24, no. 2, pp. 143-148. DOI: 10.1007/s10140-016-1462-6.
49. Dinges E., Ortner C., Bollag L., Davies J., Landau R. Osteogenesis imperfecta: cesarean deliveries in identical twins. *Int. J. Obstet. Anesth.*, 2015, vol. 24, no. 1, pp. 64-68. DOI: 10.106/j.ijoa.2014.07.006.
50. Quakernack K., Beckmann M., de Moll H. Osteogenesis imperfecta in pregnancy. *Geburtshilfe Frauenheilkd.*, 1980, vol. 40, no. 2, pp. 180-184. DOI: 10.1055/s-2008-1037215.
51. Bellur S., Jain M., Cuthbertson D., Krakow D., Shapiro J.R., Steiner R.D., Smith P.A., Bober M.B., Hart T., Krischer J., Mullins M., Byers P.H., Pepin M., Durigova M., Glorieux F.H., Rauch F., Sutton V.R., Lee B., Members of the BBD Consortium, Nagamani S.C. Cesarean delivery is not associated with decreased at-birth fracture rates in osteogenesis imperfecta. *Genet. Med.*, 2016, vol. 18, no. 6, pp. 570-576. DOI: 10.1038/gim.2015.131.
52. Cubert R., Cheng E.Y., Mack S., Pepin M.G., Byers P.H. Osteogenesis imperfecta: mode of delivery and neonatal outcome. *Obstet. Gynecol.*, 2001, vol. 97, no. 1, pp. 66-69.
53. Chen C.P., Lin S.P., Su Y.N., Huang J.P., Chern S.R., Su J.W., Wang W. Uncomplicated vaginal delivery in two consecutive pregnancies carried to term in a woman with osteogenesis imperfecta type I and bisphosphonate treatment before conception. *Taiwan J. Obstet. Gynecol.*, 2012, vol. 51, no. 2, pp. 305-307. DOI: 10.1016/j.tjog.2012.04.029.
54. Ruitter-Ligeti J., Czuzoj-Shulman N., Spence A.R., Tulandi T., Abenheim H.A. Pregnancy outcomes in women with osteogenesis imperfecta: a retrospective cohort study. *J. Perinatol.*, 2016, vol. 36, no. 10, pp. 828-831. DOI: 10.1038/jp.2016.111.
55. Anderer G., Hellmeyer L., Hadji P. Clinical management of a pregnant patient with type I osteogenesis imperfecta using quantitative ultrasonometry – a case report. *Ultraschall. Med.*, 2008, vol. 29, no. 2, pp. 201-204. DOI: 10.1055/s-2006-927241.
56. Skriabin E.G., Sorokin M.A., Akselrov M.A., Emelianova V.A., Naumov S.V., Bukseev A.N., Chuprov A.Iu. Klinicheskii sluchai primeneniia metoda intramedullarnogo osteosinteza v lechenii patologicheskogo pereloma bedrennoi kosti u 6-dnevnoi novorozhdennoi devochki s vysokoi chastichnoi kishhechnoi neprokhodimosti [A clinical case of using intramedullary osteosynthesis method in treatment of pathological femoral fracture in 6-day old newborn girl with high partial intestinal obstruction]. *Ortopediia, Travmatologija i Vosstanovitelnaia Khirurgija Detskogo Vozrasta*, 2017, vol. 5, no. 2, pp. 52-58. DOI: 10.17816/PTORS5252-58. (in Russian)
57. Akselrov M.A., Razin M.P., Emelianova V.A., Serigenko T.V., Dadasheva S.M., Svazian V.V., Akselrov A.M., Sakharov S.P., Iamshchikova E.V. Redkii sluchai vrozhdennoi vysokoi kishhechnoi neprokhodimosti v sochetanii s obratnym raspolozheniem vnutrennikh organov u rebenka [A rare case of congenital high intestinal obstruction combined with reverse arrangement of visceral organs in a child]. *Meditinskaja Nauka i Obrazovanie Urala*, 2017, vol. 18, no. 2 (90), pp. 83-86. (in Russian)
58. Belova N.A., Kostik M.M., Buklaev D.S., Popkov D.A., Popkov A.V., Gubin A.V., Ochirova P.V., Chikova I.A., Buchinskaja N.V., Asanov A.Iu., Shchepliagina L.A., Vissarionov S.V., Larionova V.I., comp. *Federalnye klinicheskie rekomendatsii (protokol) po okazaniiu meditsinskoj pomoshchi patsientam s nesovershennym osteogenezom* [Federal Clinical Guidelines (Protocol) for providing medical care to patients with osteogenesis imperfecta]. 40 p. (in Russian) Available at: <http://мороздгкб.рф/wp-content/uploads/2017/03/Федеральные-клинические-рекомендации-протокол-по-оказанию-медицинской-помощи-пациентам-с-несовершенным-osteogenezom.pdf>
59. Marini J.C., Forlino A., Bächinger H.P., Bishop N.J., Byers P.H., Paeppe A., Fassier F., Fratzl-Zelman N., Kozloff K.M., Krakow D., Montpetit K., Semler O. Osteogenesis imperfecta. *Nat. Rev. Dis. Primers*, 2017, vol. 3, pp. 17052. DOI: 10.1038/nrdp.2017.52.
60. Barros E.R., Saraiva G.L., De Oliveira T.P., Lazaretti-Castro M. Safety and efficacy of a 1-year treatment with zoledronic acid compared with pamidronate in children with osteogenesis imperfecta. *J. Pediatr. Endocrinol. Metab.*, 2012, vol. 25, no. 5-6, pp. 485-491.

Received: 25.05.2018

Information about the authors:

1. Evgenii G. Skryabin, M.D., Ph.D., Professor,
Tyumen State Medical University, Tyumen, Russian Federation,
Email:skryabineg@mail.ru
2. Irina V. Komarova, M.D.,
Perinatal Center, Tyumen, Tyumen, Russian Federation,
E-mail:irina-komarova60@mail.ru
3. Aleksandr N. Bukseev, M.D.,
Regional clinical hospital № 2, Tyumen, Russian Federation,
Email:bukseev1971@mail.ru
4. Irina I. Kukarskaya, M.D., Ph.D.,
Tyumen State Medical University, Tyumen, Russian Federation,
Perinatal Center, Tyumen, Tyumen, Russian Federation,
Email:kukarskay@mail.ru
5. Mikhail A. Akselrov, M.D., Ph.D.,
Tyumen State Medical University, Tyumen, Russian Federation,
Regional clinical hospital № 2, Tyumen, Russian Federation,
Email: akselrov@mail.ru
6. Elena B. Khramova, M.D., Ph.D.,
Tyumen State Medical University, Tyumen, Russian Federation,
E-mail: doctor.khramova@gmail.ru
7. Svetlana N. Suprunets, M.D., Ph.D.,
Regional clinical hospital № 2, Tyumen, Russian Federation,
Tyumen State Medical University, Tyumen, Russian Federation,
Email:suprunets.s@gmail.ru
8. Dmitry A. Popkov, M.D., Ph.D.,
Russian Ilizarov Scientific Centre for Restorative Traumatology and Orthopaedics, Kurgan, Russian Federation,
Email: dpopkov@mail.ru