

Distal posterior humeral plating for periprosthetic humeral fracture in a female patient

I.A. Voronkevich, P.G. Kogan, A.A. Kochish, S.A. Lasunskiy

Vreden Russian Research Institute of Traumatology and Orthopedics, Saint Petersburg, Russian Federation

A clinical case of a 70-year-old female patient with periprosthetic humeral fracture is reported. A new distal posterior humeral plate devised at our institution for nonunions and comminuted fractures of the distal humerus was used in the case. The treatment resulted in fracture healing and functional recovery of the limb at the pre-periprosthetic fracture level. Technical features of the fixator and surgical technique are described in details with cortical allograft practice used to augment thin cortical bone around the stem.

Keywords: plating, humerus, periprosthetic fracture, posterior approach, stable fixation, bone allograft

INTRODUCTION

The incidence of total shoulder arthroplasty (TSA) has increased significantly [1, 2, 3, 4]. The procedure is indicated for comminuted fractures and fracture-dislocations of the proximal humerus, glenohumeral grade III osteoarthritis, aseptic necrosis and tumors of the humeral head [1, 5]. TSA is intended to relieve pain, partially restore function to the joint, resume everyday activities and improve quality of life [2, 6].

Increased use of total shoulder arthroplasty over the past decade has led to identification of common complications including periprosthetic fracture as one of most severe ones. The prevalence of periprosthetic humerus fractures after TSA is 1.5% to 11 % accounting for 18 cases of periprosthetic fracture per 1000 procedures [1, 2, 7]. Most typical fractures occur in the lower third of the humerus at the distal tip of the humeral component or 2 to 3 cm distal off the tip [7, 8]. The primary goals of treatment are fracture union, preservation of the implant with a function of the shoulder achieved and prevention of contractures in the elbow joint [4, 9, 10]. For this, displaced bone is to be reduced and reliably fixed for early motion of the injured limb and measures to be taken to prevent intraoperative injury to the radial nerve [10, 11]. A prosthetic stem filling in the medullary canal of the proximal fragment and a thin cortical bone around the stem are major obstacles to osteosynthesis of the periprosthetic humeral fractures with bypassing screws placed in rare cases using standard plate constructs. The scenario is aggravated by absence of specialty plates

unavailable in our country to create periprosthetic solutions for lower third humeral fractures [7, 8]. Special plate has been developed and manufactured by domestic industry to address periprosthetic humerus fractures and described in the paper.

The purpose of this paper was to explore possibilities with the new posterior distal humerus plate developed at the Russian Vreden Scientific Research Institute of Traumatology and Orthopaedics (RVSRITO) to address lower third humerus fracture during operative treatment of a female patient with periprosthetic fracture.

Posterior distal combined plate intended for fixation of the fractures and nonunions in the lower third humerus was developed at the RVSRITO within the context of governmental research assignments (Patent № 163085 dtd 10.10.16). The fixator (**Fig. 1**) is manufactured by Russian company «DC» and a component of a kit of figurate plates approved for clinical usage.

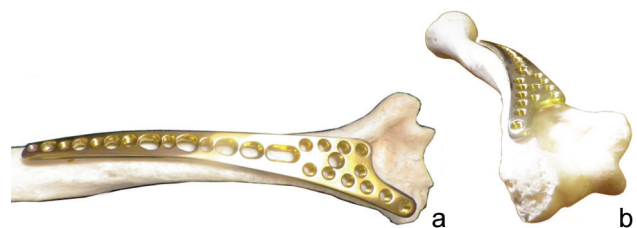

Fig. 1 Posterior distal combined plate attached to artificial humerus showing (a) back view; (b) view from the elbow joint

The plate is anatomically contoured in the posterior aspect of the humerus and supplied with sagittal curvatures, spirally spun to bypass radial nerve and avoid contact with the nerve. The diaphyseal part of the plate has intermediately sized compression holes for 3.5 mm and 4.5 mm cortex screws to be used according to specific patient anatomy. The holes alternate with 3.5 mm angle-fixed holes that are indicated to provide more stability for osteoporotic bone. The distal fixation incorporates a wider portion of the plate with humeral condyle attachment and eleven 3.5 mm angle-fixed holes for local osteoporosis in lower third nonunion.

Designers' intention was to use the plate for comminuted fractures and nonunions in the lower third of the humerus shaft. However, it was the first case with the plate used to address periprosthetic humerus fracture. The clinical instance described in the article has shown advantages of the fixator for non-standard surgical solution and expanded indications to the application.

Case report

A 70-year-old female patient A., born 19.05.2015, presented at the RVS RITO with pathological mobility in the middle third of the left humerus, numb thumb on the left side with the absence of active extension. Her medical history included four-part fracture-dislocation of the proximal humerus on the left side she sustained due to fall from standing height in 2012. She had undergone a primary plating and re-plating of the left humerus via anterior transdeltoid approach at one of municipal hospitals. The treatments resulted in aseptic necrosis of the left humeral head, secondary deforming arthritis and rotator cuff degeneration and finally to poor function of the left shoulder and deficiency in active abduction. Total Neer C.S. score [10] was 26 indicating to a poor outcome. The DePuy Delta Xten™ reverse shoulder system was employed for total shoulder replacement procedure performed for the patient at the RVS RITO on 19.11.2012 with indications identified (**Fig. 2**).

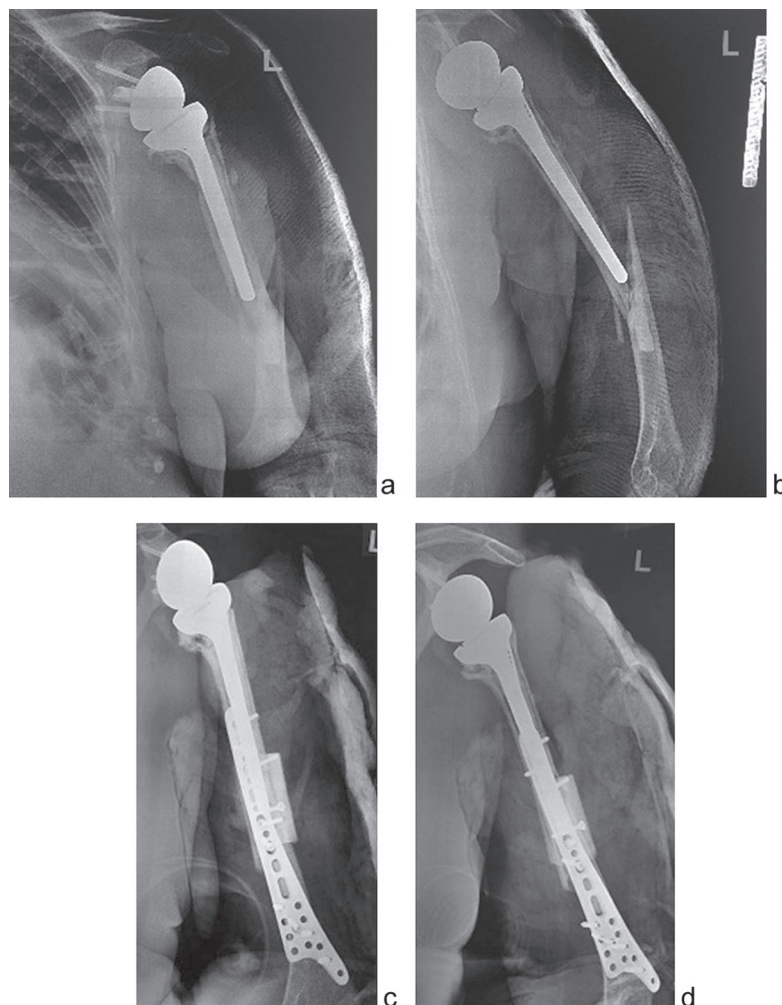


Fig. 2 Radiographs of the left humerus of the 70-year-old female patient A. taken on admission at the RVS RITO on 19.05.2015 showing (a) anterolateral view, (b) lateral view after osteosynthesis, (c) postoperative AP view, (D) lateral view(inclined)

Postoperative period was uneventful. VAS score improved from 7 to 5 at 18-month follow-up. The patient showed active abduction of 50° in the left shoulder, frontal flexion of 70°, extension of 45°, external rotation of 20° and internal rotation of 30°. Neer score measured 46 points indicating to a fairly functioning shoulder. On the whole, the patient reported satisfaction with the function of the left upper limb being able to accomplish self-care activities of daily living.

However, the patient sustained periprosthetic fracture of the left humerus shaft due to a fall from standing height on 17.05.2015 and she sought medical treatment at the RVS RITO. The patient was seen at our hospital on 19.05.2015 and diagnosed with pathological mobility in the lower half of the left humeral shaft, bone crepitation, painful axial loading and absence of active extension of the left thumb. Postoperative scar 15 cm long with no signs of infection was observed on the anterior aspect of the left shoulder with anterior portion of deltoid muscle being evidently atrophic. Radiographs showed oblique fracture of the left humerus at the distal tip of the humeral component (**Fig. 2 a, b**) classified as type B1 according to the AO [12] and the Worland R.L. [10] classification system for periprosthetic humerus fractures. This type of fracture suggests either conservative treatment or open reduction and stable bone fixation to allow early mobility [4, 8, 9]. Radial nerve palsy was observed. The tactics of surgical treatment included open reduction under direct visual control and stable bone fixation with the plate following radial nerve injury repair. Preoperative discussions ended up with the new figurate plate developed at the RVS RITO to be used for the surgical treatment.

The choice of the fixator was based on the authors' experience with the plate applied for fractures and nonunions of lower third of the humeral shaft and the configuration ensured the possibility of introducing screws and bypassing the humerus component. The expanded fixation characteristics of the device offered an opportunity to rely on continuous stable fixation with prognostic delayed union of periprosthetic fracture. In addition to that, the plate was an attractive option in terms of costs compared with international alternatives and be covered by obligatory medical insurance fund.

On 21.05.2015 periprosthetic humerus fracture was fixed with the plate and screws offered using bone allograft. The technology of the device suggests posterior approach. Intact radial nerve was visualised with the proximal and distal fragments exposed and the top of the humeral component poking out. Fixation of the humeral component in the proximal bone was assessed as stable. Then the distal combined plate was placed over bone fragments avoiding conflict with the radial nerve, and fixation screws bypassing the stem introduced. Cortical allograft with two cortex screws providing side-to-side compression for more reliable proximal stability was placed on the surface of the proximal humerus. The length of surgical intervention was 110 minutes with blood loss of 400 ml. Postoperative radiographs are presented in **Fig. 2 c, d**.

Postoperative period was uneventful. Skin sutures were removed after 12 postoperative days. Postoperative course of rehabilitation was administered for the patient. Her condition was satisfactory on discharge. With edema settled immobilisation of the upper limb with the splint was replaced by a sling and elbow motion allowed.

The patient had follow-up visits at 3, 6 and 12 months. At 12 months the patient showed functioning of the left upper limb being equal to that seen at one year of total shoulder replacement. The Neer shoulder assessment scale measured 45 [13] and 27 with the Oxford Shoulder Score [3].

The findings are in line with the data reported by foreign authors [8, 14, 15, 16] reconfirming the fact that periprosthetic humerus fractures are among the most challenging complications of shoulder arthroplasty and the treatment can ideally result in a functional result that would be not better than that obtained after replacement.

Functionally insignificant limitation in elbow extension by 15° with full flexion (**Fig. 3**) led to insignificant decrease in the Diasbility of the Arm, Shoulder and Hand (DASH) score of 35 points. Complete union of periprosthetic humerus fracture was seen on CT scan of 19.06.2016.

The Visual Analog Scale (VAS) score for pain and patient satisfaction measured 5 and correlated with the score measured at 18 months of the left shoulder arthroplasty prior to the periprosthetic fracture.

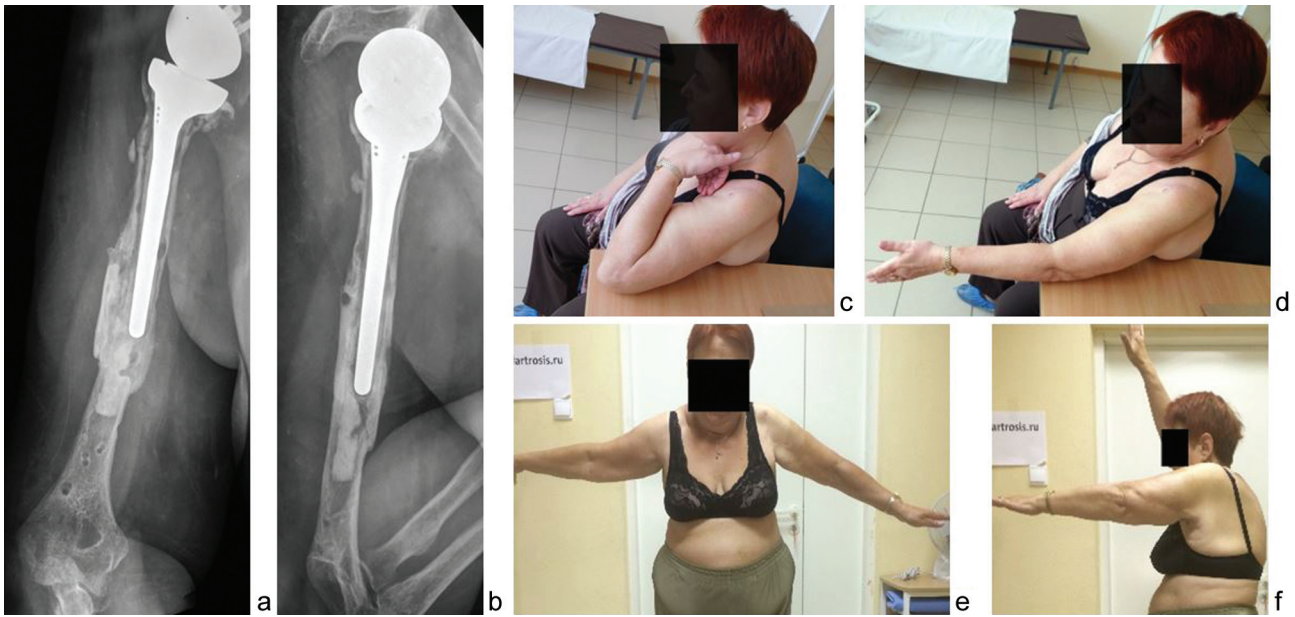


Fig. 3 Radiological and clinical appearance of the 70-year-old female patient A. at one year following fixation of the left humerus using the figurate plate offered and bone allograft (the fixator removed) showing (a) anteroposterior view, (b) lateral view, (c) flexion in the elbow joint, (d) extension in the elbow joint, (e) abduction in the shoulder, (f) extension in the shoulder

DISCUSSION

Difficulties of fixation of periprosthetic humerus fractures with stability of the humerus component to be maintained are associated with accurate reduction and adequate bone fixation, maximally sparing attitude towards the bone and prosthetic components to allow early rehabilitation preserving the function of the shoulder and elbow joints. The stem of the humeral component in the proximal fragments hinders bicortical screw placement that results in limited postoperative loading on the operated upper limb and requires external immobilisation. The procedures are technically demanding due to specific surgical approach and the risk to the radial nerve and vessels. Periprosthetic fractures may fail to unite with a wide range of consolidation timing even with the technique strictly adhered to. Nonunion is reported to occur in 9 to 35% of the cases. Delayed consolidation primarily develops due to the lack of endosteal circulation in the proximal fragment at the stem and incomplete removal of bone cement at the distal portion [4, 5, 9, 10, 11, 16].

It should be noted that intraoperative application of anatomically contoured plate is technically appropriate and reproducible by surgeons. Figurate plate is practical in avoiding intraoperative injury to the radial and ulnar nerves providing the possibility of placing proximal screws bypassing the humeral component. The advantage with the plate allows

for reliable bone fixation of periprosthetic humerus fractures maintaining function of the glenohumeral and elbow joints.

The metal construct does not incorporate polyaxial locking screw-plate designs of the Polyax plate (DePuy-Synthes), Peri-Loc from Smith & Nephew, NCB from Zimmer-Biomet, and the Synthes screw and cable system that is successfully used by many authors [8, 10, 16]. Our inexpensive construct of the plate was practical in providing high intraoperative stability and reliable fixation. The plate design incorporated original augment technique of additional fixation reinforced with allograft. Allograft augment is used to improve fixation of periprosthetic humerus fractures with cable systems in different hospitals [8, 16]. In our case the augment was fixed using oval holes made for autografts placed on the anteromedial and anterolateral surfaces in nonunions. Oval holes were used to augment fixation of the allograft pulled up to the anterior surface of the bone at the fracture level and thin proximal fragment. The risk of screw loosening was considerably lower with allograft. The result achieved was as good as the one of circular humerus envelopment provided with Synthes Cable System and deprived of its shortcomings including cable related atrophy with cutting through the bone effect and loss of fixation. Structural cortical graft

of the femoral shaft produced by the RVS-RITO transplant unit with chemical sterilization in Beliakov's modified medium was used in our clinical instance [17]. A fair functional outcome achieved in the case of complicated periprosthetic humerus fractures is in line with reported results of the foreign peers [4, 5, 9, 10, 11, 16]. The clinical case was reported at the 1258th meeting of Orthopaedic and Trauma Research Society of Saint Petersburg and Leningradskaya Oblast taking

into consideration the complicated pattern of the fracture, intraoperative application of the new plate, bone healing achieved and earlier placed shoulder prosthesis preserved. The presentation made on 25.05.2016 was approved with the tactics of treatment and type of fixator used and functional result assessed as satisfactory enough in the clinical scenario. There also suggestions made to accumulate clinical experience with repair of periprosthetic humerus fractures using the figurate plate.

CONCLUSION

The clinical observation showed real possibilities, technical improvements and quite a satisfactory result of non-standard surgical treatment of the patient with periprosthetic humerus fractures using a new figurate plate offered for osteosynthesis. All the goals were pursued intraoperatively ensuring stable bone fixation, prevention of iatrogenic injuries to major nerve trunks, early rehabilitation and bone union confirmed by computed tomography scans

and resulted in the satisfactory functional outcome and improved pain at 12-month follow-up. The new figurate plate successfully applied for the above clinical observation can be advocated for a wider clinical usage. The plate offered can be efficaciously used for both the fractures and nonunions in the lower third of the humerus shaft and periprosthetic humerus fractures at the distal tip of the humerus component of the total replacement system.

REFERENCES

1. Zaraiskii A.S., Zoria V.I. Endoprotezirovaniye plechevogo sustava. Problemy i resheniia [The shoulder arthroplasty. Problems and solutions]. *Moskovskii Khirurg. Zhurn.*, 2011, no. 4, pp. 58-64. (In Russ.)
2. Maikov S.V., Mikailov I.M., Ptashnikov D.A. Rezul'taty endoprotezirovaniia plechevogo sustava u bol'nykh s novoobrazovaniiami proksimal'nogo otdela plechevoi kosti [Results of the shoulder arthroplasty in patients with proximal humeral tumors]. *Travmatologiya i Ortopediya Rossii*, 2014, no. 4, pp. 27-35. (In Russ.)
3. Constant C.R., Murley A.H. A clinical method of functional assessment of the shoulder. *Clin. Orthop. Relat. Res.*, 1987, no. 214, pp. 160-164.
4. Mineo G.V., Accetta R., Franceschini M., Pedrotti Dell'Acqua G., Calori G.M., Meersseman A. Management of shoulder periprosthetic fractures: our institutional experience and review of the literature. *Injury*, 2013, vol. 44, no. Suppl. 1, pp. S82-S85. DOI: 10.1016/S0020-1383(13)70018-4.
5. Bohsali K.I., Wirth M.A., Rockwood C.A. Jr. Complications of total shoulder arthroplasty. *J. Bone Joint Surg. Am.*, 2006, vol. 88, no. 10, pp. 2279-2292. DOI: 10.2106/JBJS.F.00125.
6. Nenashev D.V., Varfolomeev A.P., Maikov S.V. Analiz otdalennykh rezul'tatov endo-protezirovaniia plechevogo sustava [The analysis of long-term results of the shoulder arthroplasty]. *Travmatologiya i Ortopediya Rossii*, 2012, no. 2, pp. 71-78. (In Russ.)
7. Tikhilov R.M., Shubniakov I.I., Nenashev D.V., Ambrosenkov A.V., Ardatov S.V. Perelomy kostei verkhnei konechnosti [Fractures of the upper limb bones]. In: Kotelnikov G.P., Mironov S.P., eds. *Travmatologiya: nats. rukovodstvo [Traumatology: National Guidelines]*. M., GEOTAR-Media, 2011, chapter 13, pp. 464-541. (In Russ.)
8. Sanchez-Sotelo J., O'Driscoll S., Morrey B.F. Periprosthetic humeral fractures after total elbow arthroplasty: treatment with im-plant revision and strut allograft augmentation. *J. Bone Joint Surg. Am.*, 2002, vol. 84-A, no. 9, pp. 1642-1650.
9. Groh G.I., Heckman M.M., Wirth M.A., Curtis R.J., Rockwood C.A. Jr. Treatment of fractures adjacent to humeral prostheses. *J. Shoulder Elbow Surg.*, 2008, vol. 17, no. 1, pp. 85-89. DOI: 10.1016/j.jse.2007.05.007.
10. Worland R.L., Kim D.Y., Arredondo J. Periprosthetic humeral fractures: management and classification. *J. Shoulder Elbow Surg.*, 1999, vol. 8, no. 6, pp. 590-594.
11. Kumar S., Sperling J.W., Haidukewych G.H., Cofield R.H. Periprosthetic humeral fractures after shoulder arthroplasty. *J. Bone Joint Surg. Am.*, 2004, vol. 86-A, no. 4, pp. 680-689.
12. Duncan C.P., Haddad F.S. The Unified Classification System (UCS): improving our understanding of periprosthetic fractures. *Bone Joint J.*, 2014, vol. 96-B, no. 6, pp. 713-716. DOI: 10.1302/0301-620X.96B6.34040.
13. Neer C.S. 2nd. Displaced proximal humeral fractures: part I. Classification and evaluation. 1970. *Clin. Orthop. Relat. Res.*, 2006, vol. 442, pp. 77-82.

14. Boyd A.D. Jr., Thornhill T.S., Barnes C.L. Fractures adjacent to humeral prostheses. *J. Bone Joint Surg. Am.*, 1992, vol. 74, no. 10, pp. 1498-1504.
15. Hudak P.L., Amadio P.C., Bombardier C. Development of an upper extremity outcome measure: the DASH (disabilities of the arm, shoulder and hand). The Upper Extremity Collaborative Group (UECG). *Am. J. Ind. Med.*, 1996, vol. 29, no. 6, pp. 602-608. DOI: 10.1002/(SICI)1097-0274(199606)29:6<602::AID-AJIM4>3.0.CO;2-L.
16. Greiner S., Stein V., Scheibel M. Periprosthetic humeral fractures after shoulder and elbow arthroplasty. *Acta Chir. Orthop. Traumatol. Cech.*, 2011, vol. 78, no. 6, pp. 490-500.
17. Rykov Iu.A. Sravnitel'naia otsenka morfologicheskoi evoliutsii sukhozhil'nykh i kostnykh allotransplantatov, zagotavlennykh raznym sposobom [Comparative evaluation of morphological evolution of the tendon and bone allografts prepared in different ways]. *Travmatologiya i Ortopediya Rossii*, 2010, no. 1, pp. 172-174. (In Russ.)

Received: 12.05.2017

Information about the authors:

1. Igor' A. Voronkevich, M.D., Ph.D., Professor,
Vreden Russian Research Institute of Traumatology and Orthopedics, Saint Petersburg, Russian Federation,
Email: dr_voronkevich@inbox.ru
2. Pavel G. Kogan, M.D.,
Vreden Russian Research Institute of Traumatology and Orthopedics, Saint Petersburg, Russian Federation
3. Andrei A. Kochish, M.D.,
Vreden Russian Research Institute of Traumatology and Orthopedics, Saint Petersburg, Russian Federation
4. Sergei A. Iasunskiy, M.D., Ph.D., Professor,
Vreden Russian Research Institute of Traumatology and Orthopedics, Saint Petersburg, Russian Federation