

Two-year results of spinal fracture treatment using carbon implants (Multicenter study)

S.V. Kolesov¹, D.A. Kolbovskiy², V.V. Shvets¹, V.V. Rerikh³, A.V. Vishnevskiy⁴, N.S. Morozova¹, I.V. Skorina¹, D.S. Gorbatyuk¹

¹National Medical Research Center Of Traumatology And Orthopedics n.a. N.N. Priorov, Moscow, Russian Federation;

²Russian Medical Academy of Continuing Professional Education, Moscow, Russian Federation;

³Novosibirsk Research Institute Of Traumatology And Orthopaedics N.a. Ya.I. Tsivyan, Novosibirsk, Russian Federation;

⁴St. Petersburg Research Institute of Phthisiopulmonology, Saint Petersburg, Russian Federation

Introduction A good alternative to bone autograft fusion is the utilization of implants produced from non-biological materials. Such implants can reduce the duration of surgery as well as tissue morbidity, while meeting the mechanical strength and osteoconductivity requirements. According to the study results, carbon is a promising material for interbody fusion because of its biocompatibility and osseointegration, as well as an elastic modulus that is close to bone tissue. **Methods** From 2015 to 2017 a randomized multicenter study was conducted. Three centers took part in the study: the National Medical Research Center of Traumatology and Orthopedics named after N.N. Priorov; Novosibirsk Research Institute for Traumatology and Orthopedics named after Ya.L. Tsivyan; Saint-Petersburg National Phthisiopulmonology Research Institute. One hundred thirteen patients with vertebral body fractures were included in the study and underwent surgical treatment using posterior interbody fusion. In 75 patients (66.37 %, group I) carbon-carbon implants were used, and in 38 patients (group II) – titanium cages. Patient examination was conducted using one protocol, preoperative examination methods and at 6, 12, and 24 month follow-ups, and included VAS score, SF-36 questionnaire, and ASIA scale, as well as CT examination and fusion progress assessment according to G. Tan's classification. **Results** The 2-year study showed statistically significant differences between index (carbon implants) and control (titanium cages) groups. Although bone fusion progressed very slowly in the study group (in 86 % of cases no bone fusion was observed at first follow-up 6 months after surgery), the VAS and SF-36 scores were comparable in study and control groups. **Discussion** Carbon implants are characterized not only by high mechanical strength but also by a significant ability to osteoconductivity that allow for effective bone-carbon fusion due to their porous structure and an elastic modulus of 20–30 GPa, that is comparable to that of bone tissue. These characteristics were confirmed by radiological data (absence of implant subsidence in 38 out of 58 patients (65.51 %) at 24 month follow-up. Titanium implants with an elastic modulus of 80 GPa had a subsidence rate of 100 %.

Keywords: vertebral fracture, fusion, carbon implant

INTRODUCTION

Combination of strength and osteoconductivity is an extremely important property of implants used in spinal surgery. It is no doubt that the “gold” standard for performing spinal fusion is autologous bone [1]. However, despite the merits of autologous bone, there are a number of shortcomings in its use such as autograft resorption, pseudarthrosis, autograft non-fusion with the recipient site of the vertebral motor segment, as well as an additional surgical trauma, pain in the area of autograft harvesting (donor site morbidity) [2–6]. There are also drawbacks with the use of allogeneous bone, which is associated with a rather complicated technology of harvesting, lyophilization, and sterilization. Moreover, there is a danger of recipient infection, possible immunological conflict, ethical moral and religious aspects that should be considered [7, 8].

An alternative for spondylodesis is the use of implants from non-biological materials, which would reduce the duration and invasiveness of the operation, but also would meet the demands of strength and osteoconductivity. Most implants made of artificial materials have no such properties, and therefore they play the role of foreign bodies around which a connective tissue case is formed.

A promising material for spinal fusion is carbon, which, in comparison with titanium or PEEK material (polyetheretherketone implants), features not only biological inertness, but also tropism to bone tissue, as well as an elastic modulus close to that of bone tissue [9, 10].

Biological compatibility allows the widespread use of such implants. Carbon is chemically inert, does not dissolve in organic and inorganic

☞ Kolesov S.V., Kolbovskiy D.A., Shvets V.V., Rerikh V.V., Vishnevskiy A.V., Morozova N.S., Skorina I.V., Gorbatyuk D.S. Two-year results of spinal fracture treatment using carbon implants (Multicenter study). *Genij Ortopedii*, 2019, T. 25, No 3, pp. 360-367. DOI 10.18019/1028-4427-2019-25-3-360-367. (In Russian)

solvents, and does not interact with alkalis, acids, salts, organic and biologically active compounds. Carbon materials are also resistant to corrosion, as they have great electropositive potential. Its relative technological simplicity and low production cost, plasticity during intraoperative processing, and diamagnetic properties that allow CT and MRI examinations of the spine without “interference” in the area of the involved spinal motion segment is no less importance [11–14]. The combination of these factors attributes carbon implants to the material of choice and the subject for a comprehensive study.

Study design: a randomized multicenter study.

Purpose: To conduct a comparative analysis of the properties of carbon implants and classical titanium

mesh implants in the surgical treatment of vertebral body fractures.

Study objectives:

- evaluation of patients’ condition after surgical treatment (short- and long-term) using carbon implants and classic titanium mesh implants using VAS and SF - 36 questionnaires;
- assessment of subsidence of carbon implants and classical titanium mesh implants in the postoperative period (early and long-term);
- assessment of fusion with the use of carbon implants and classical titanium mesh implants in the postoperative period (early and long-term);
- assessment of the bone-to-carbon conglomerate when using carbon-to-carbon implants in the postoperative period (early and long-term).

MATERIAL AND METHODS

In the period from 2015 to 2017, the Federal State Budgetary Institution *National N.N. Priorov Medical Research Center for Traumatology and Orthopedics* of the Ministry of Health of the Russian Federation, Federal State Budgetary Institution *Novosibirsk I.L. Tsivyan Research Institute of Traumatology and Orthopedics* of the Ministry of Health of the Russian Federation and the Federal State Budgetary Institution *St. Petersburg Research Institute of Phthisiopulmonology* of the Ministry of Health of the Russian Federation conducted a randomized multicenter study.

Over the specified period, one hundred and thirteen patients were studied who underwent surgical treatment for vertebral fractures at various levels of the spine, and namely, cervical spine – 11 cases (9.73 %), thoracic spine – 39 cases (34.51 %), and lumbar spine – 63 cases (55.75 %). Among these patients, carbon-to-carbon implants (CCI) were used for interbody corporodesis in 75 cases (66.37 %, group I), and in 38 cases (33.63 %, group II) classical titanium mesh implants were implanted (TMI).

Selection and observation of patients was carried out according to a single protocol of inclusion and exclusion criteria (Table 1), examination methods before surgery, after surgery and at follow-ups of 6, 12, 24 months: VAS questionnaires, SF-36, ASIA, computed tomography (CT) of the involved vertebral spinal motion segment. Fusion was evaluated according to the classification of G. Tan (Fig. 1). Age

and sex characteristics in both groups of patients met the criteria for inclusion and exclusion of patients in the study and did not have certain patterns. Randomization was achieved by randomly including patients in comparison groups I and II. The number of groups is proportional to the size of the initial patient populations, among which randomization was carried out. In each of the clinical centers, the decision on the size of the groups was made independently, based on the amount of available data (in particular, the number of processed medical records).

Traffic accidents prevailed among the causes of spinal injuries and all 75 subjects (66.37 %) were passengers during car accidents; the injury was a result of falls from a height of 5-10 meters in 25 cases (22.12 %). Five patients (4.42 %) sustained vertebral injuries due to low-energy trauma. It should be noted that these patients fell into the inclusion criteria by age; however, the results of densitometry of the femoral necks were within the norm.

The nature of the fracture was determined according to Denis classification; there were more patients with type A and B fractures than with C and D types (Table 2). Neurological status according to the ASIA system showed the absence of a neurological deficit in 57 %, and gross symptoms were detected in 10 % (Table 3).

Pain was evaluated according to VAS scale (Table 4) and indirectly by the quality of life questionnaire (SF-36) after the injury, after the operation and in the postoperative period (Table 5).

Table 1

Inclusion/exclusion criteria

Inclusion criteria	Exclusion criteria
<ul style="list-style-type: none"> • Gender, males and females • Ages (range: 18-55) • Injuries of cervical, thoracic and lumbar spine with the following clinical and radiographic manifestations: <ul style="list-style-type: none"> - unstable fractures of C3-L5 vertebral bodies - fracture-dislocations of C3-L5 vertebral bodies - compression fractures - burst fractures - complicated fractures - non-complicated fractures 	<ul style="list-style-type: none"> • Asymptomatic course • Surgical intervention requiring resection at more than one level • Previous interventions at cervical, thoracic and lumbar spine • Concomitant chronic infection or tumour disease • T-criterion lower than 1.5 (roentgen densitometry of the Ward's area) • Diseases of parathyroid gland

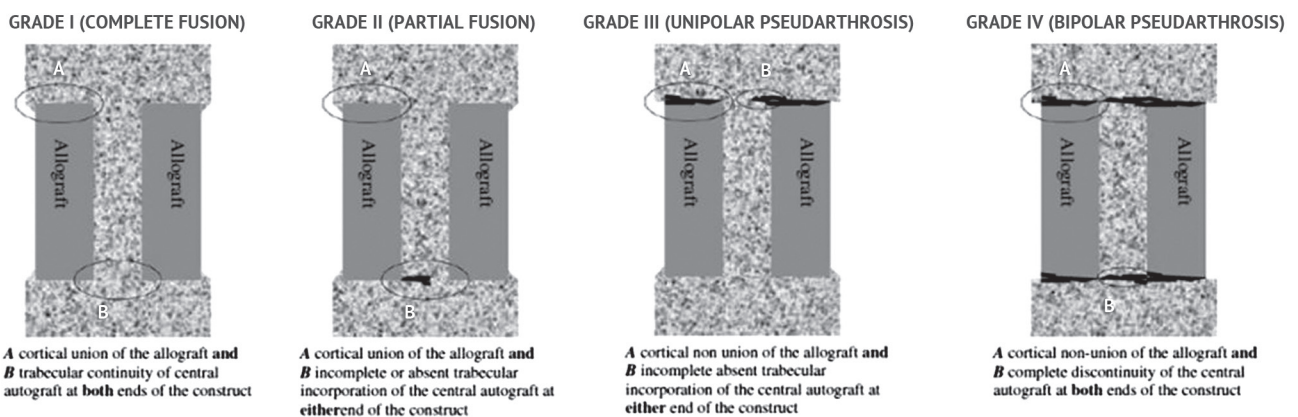


Fig. 1 Classification of fusion according to G. Tan

Table 2

Fracture types according to Denis classification of spinal trauma

Groups	Denis classification				
	A	B	C	D	E
Group I (n = 75)	38	19	6	12	0
Group II (n = 38)	17	13	2	6	0

Table 3

Neurologic status according to ASIA impairment scale

	Group I			Group II		
	Before surgery	12 months after surgery (n = 60)	24 months after surgery (n = 58)	Before surgery	6 months after surgery (n = 36)	12 months after surgery (n = 30)
A	4	4	4	1	1	1
B	3	2	2	4	3	2
C	17	15	12	1	1	0
D	16	2	0	2	0	0
E	35	37	40	30	31	27

Table 4

Comparison of VAS results in patients of groups I and II

Groups	Periods of study			
	Before surgery	6 months after surgery	12 months after surgery	24 months after surgery
Group I	8.5 ± 3.4	3 ± 2.1	1 ± 0.9	2 ± 1.2
Group II	9.3 ± 4.2	2 ± 1.3	2 ± 1.1	2 ± 1.2
P	0.678	0.230	0.458	0.920

Table 5

Comparison of SF-36 results in patients of groups I and II

Состояние	Groups	Periods of study			
		Before surgery	6 months after surgery	12 months after surgery	24 months after surgery
Physical health	I	32.4 ± 18.3	32.4 ± 14.7	63.5 ± 29.4	72.3 ± 39.4
	II	30.5 ± 20.1	30.5 ± 19.1	66.4 ± 36.8	70.2 ± 33.5
	P	0.532	0.411	0.379	0.512
Mental health	I	42.5 ± 17.8	32.4 ± 12.7	76.3 ± 24.6	79.5 ± 31.8
	II	41.3 ± 21.3	30.5 ± 18.9	78.5 ± 934.2	78.2 ± 26.5
	P	0.371	0.665	0.411	0.398

Statistical analysis included an assessment of differences in the success of fusion using the chi-square method with Fisher's correction (the correction was taken into account due to a small (less than 30) number of patients in the samples). Comparison by this method was conducted between groups I and II of patients separately for periods of 6, 12, and 24 months. Student's t-test was used for comparison of the results of the VAS and SF-36 questionnaires. In all cases, $p = 0.05$ was taken as the level of statistical significance. The calculations were performed using IBM SPSS Statistics 22 software.

Given the fact that all patients had anterior and middle column injuries in 78 % of cases and all three columns were injured in 32 % of cases, surgical treatment was aimed to restore spinal support by creating interbody fusion with additional dorsal or

ventral stabilization of the spinal motion segment by metal implants. In the cervical spine, resection of the damaged vertebral body was performed with the ventral method, an interbody corporodesis and fixation with a plate followed (Fig. 2). In the thoracic and lumbar spine, the first stage was dorsal transpedicular stabilization of the affected spine, and the second stage was ventral resection of the damaged vertebral body and interbody corporodesis with an implant. It should be noted that, when using the CCI, the autologous bone (resected rib) was laid on the lateral surface of the implant (in the case where the ends of the autologous fragment contacted with the surfaces of the vertebrae (Fig. 3, 4)), or in the longitudinal canal of the CCI (Fig. 5). In TMI cases, the autologous bone was fitted inside the grid (Fig. 6).

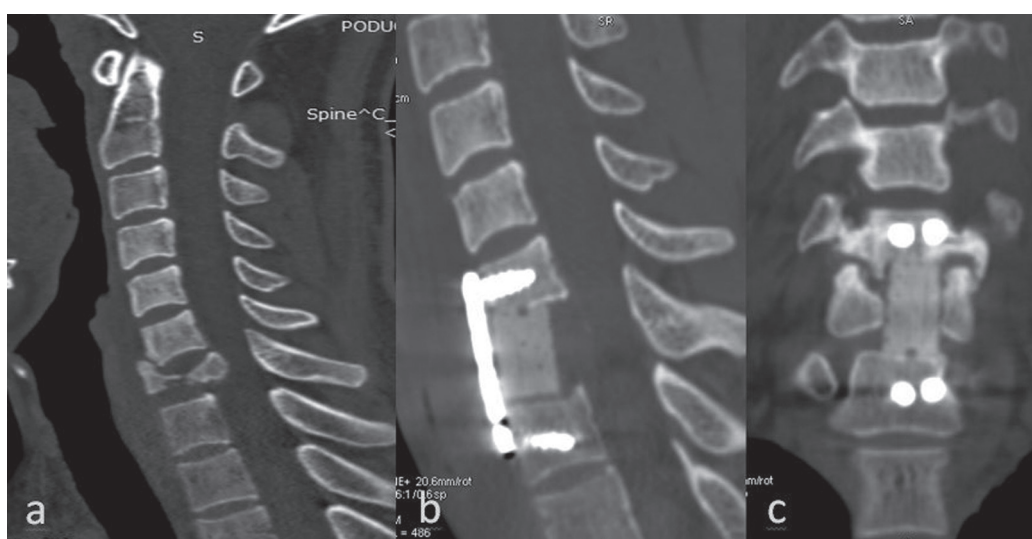


Fig. 2 Fracture of the C7 vertebra, C type according to Denis **a**; 24 months after the operation: resection of the C7 vertebral body with the interbody corporodesis of the CCI and ventral stabilization with a plate **b, c**

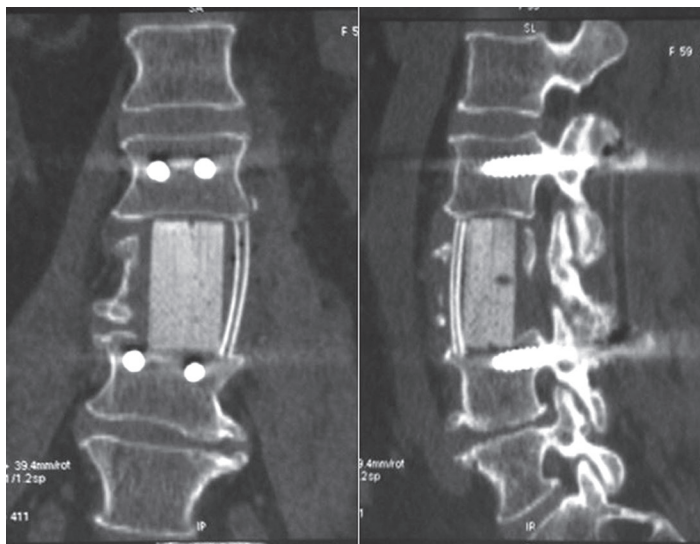


Fig. 3 Fracture of the L2 vertebra, type B according to Denis. 20 months after surgery: resection of the vertebral body with interbody corporodesis with CCI and autograft from the resected rib

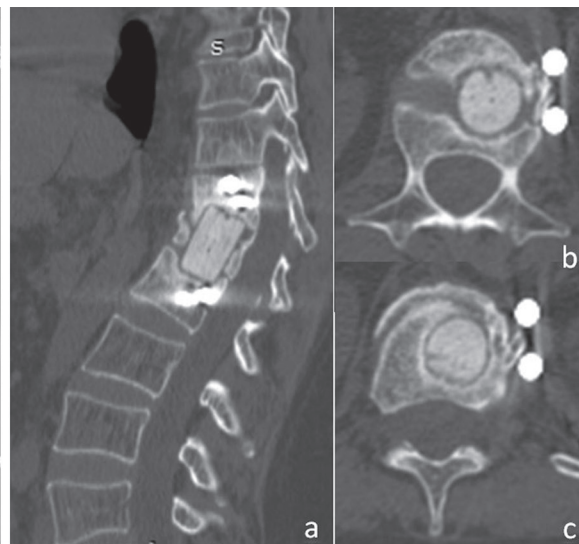


Fig. 4 Fracture of the L1 vertebra, D type according to Denis: 22 months after the operation: **a** resection of the vertebral body with interbody corporodesis with CCI and autograft from the resected rib; **b, c** spinal fusion of autograft (rib) and vertebral body

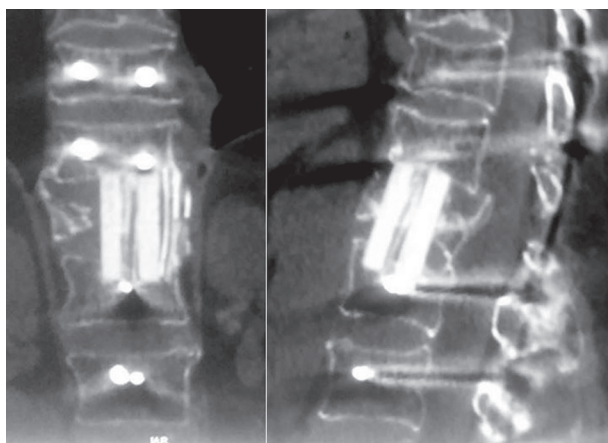


Fig. 5 Fracture of the L1 vertebra, D type according to Denis. 24 months after surgery: resection of the vertebral body and interbody corporodesis with CCI and autograft from the resected rib inside the implant

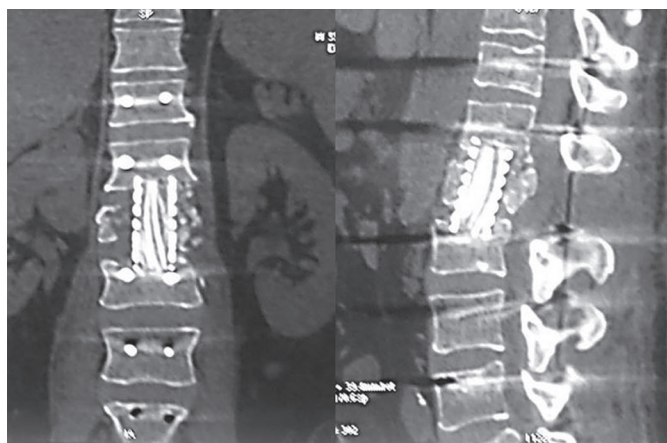


Fig. 6 Fracture of the L1 vertebra, D type according to Denis. 24 months after surgery: resection of the vertebral body and interbody corporodesis with TMI and autobone from the resected rib inside the implant

RESULTS

We were able to follow-up 101 patients (89.38 % of the initial number) up to six months after surgery (group I – 65 persons; group II – 36 persons); 90 patients (79.65 % of the initial number) were studied after 12 months (group I – 60 persons; group II – 30 persons) and 87 people (76.99 % of the initial number) after 24 months (group I – 58 persons; group II – 29 persons).

Analysis of clinical manifestations in the postoperative period in both groups corresponded to the standard of this process and did not have certain patterns in both groups, which is reflected in the results of VAS and SF-36 in the postoperative

follow-ups (Tables 4 and 5). Both groups had positive neurological dynamics, but not related to the type of implant (Table 3). None of the patients had complications associated with the destruction of both types of implants or instability of transpedicular screws.

Examination of patients in the postoperative period was focused on the findings of the radiological methods for studying the spinal motion segment involved: maintaining the local kyphosis angle, implant subsidence (Table 6), osteoresorption zone development, and signs of bone-to-carbon block formation (Table 7).

Table 6

Implant subsidence at 6, 12 and 24 months after surgery in groups I and II

	Group I			Group II		
	6 months after surgery (n = 65)	12 months after surgery (n = 60)	24 months after surgery (n = 58)	6 months after surgery (n = 36)	12 months after surgery (n = 30)	24 months after surgery (n = 29)
Endplate of the caudal vertebra (CV)	0	14 (23 %)	19 (32 %)	29 (80.5 %)	20 (66 %)	14 (48 %)
2 mm lower the CV endplate	0	0	1 (1.7 %)	7 (19.4 %)	6 (20 %)	9 (31 %)
3 mm lower the CV endplate	0	0	0	0	4 (13 %)	5 (17 %)
4 mm lower the CV endplate	0	0	0	0	0	1 (3.4 %)
5 mm lower the CV endplate	0	0	0	0	0	0

Table 7

Fusion results according G. H. Tan after 6,12 and 24 months post-surgery in groups I and II

	I группа			II группа		
	6 months after surgery (n = 65)	12 months after surgery (n = 60)	24 months after surgery (n = 58)	6 months after surgery (n = 36)	12 months after surgery (n = 30)	24 months after surgery (n = 29)
I	0	0	1 (1,7 %)	9 (25 %)	19 (63 %)	23 (79 %)
II	0	0	2 (3.4 %)	8 (22 %)	10 (33 %)	5 (17 %)
III	0	0	4 (6.8 %)	19 (52.7 %)	0	0
IV	65 (100 %)	60 (100 %)	50 (86 %)	2 (5.5 %)	1 (3.3 %)	1 (3.4 %)

According to the CT study six months after surgery in 65 patients of group I (86.67 % of the initial number), the position of the implant did not change, there were no signs of subsidence, but signs of bone-to-carbon block formation were absent. In group II, the implant subsidence was not more than 2 mm beyond the border of the caudal vertebra endplate in 29 (80.5 %) patients, but there was neither change in the position of the implant itself nor osteoresorption around transpedicular screws; fusion of grade I–II was detected in 47 % (17 patients), of which 9 (25 %) had grade I and 8 patients (22 %) grade II. Fusion of grade III according to Tan was revealed in 19 patients (52.7 % of cases), of grade IV only in two patients (5.5 % of cases).

After one year in group I, all remaining patients showed no signs of bone-to-carbon block formation, but there were no signs of implant displacement either. Angular kyphosis in the region of the spinal motion segment was not observed.

In group II, six patients (20 %) showed formation of bone block and implant subsidence of 2 mm lower the end of the caudal vertebra and four patients (13 %) had subsidence of 3 mm; however, these changes did not lead to angular kyphosis and instability. Fusion according to Tan classification was: grade I in 19 patients (63 % of cases), grade II in 10 patients (33 % of cases). Fusion of grade III was none and

grade IV was found in only one patient (3.3 % of cases).

At two years after surgery in group I, signs of subsidence below the border of the endplate were not detected in 19 patients (32.76 % of cases), one patient had it of no more than 2 mm (1.72 % of cases), subsidence of 3 mm did not occur in any of the patients. Angular kyphosis did not develop, the formation of a bone-to-carbon block of grades I–II according to Tan was observed in 3 patients (in 5.1 % of cases), of which grade I was one patient (1.7 %), and two patients had grade II (3.4 %). Also, four patients at the time of the follow-up showed Tan's grade III fusion (6.8 % of the number of available follow-up cases of group I).

In group II, good formation of fusion in 25 patients (86.2 % of cases) and implant subsidence of more than 2 mm was detected; subsidence of up to 3 mm was noted in five of them (17.24 % of patients in group II available at this follow-up).

According to the results of the statistical analysis, highly significant ($p < 0.01$ with a threshold value of $p = 0.05$) differences were noted both in the rate of spinal fusion and in the frequency of implant subsidence to a certain level, which indicates a lower fusion formation in patients with carbon implants, and also a much less "sagging" of such implants compared to titanium ones. The chi-square method

with Fisher correction was used for calculations. Statistical differences according to the results of the VAS and SF-36 questionnaires were studied by the

Student t-test and were not found between the two groups at all follow-ups (see Tables 4 and 5; in all cases, $p >> 0.05$).

DISCUSSION

The problem of osseointegration of implants used for interbody corporodesis in spinal surgery is directly related to their osteoconductive properties such as porosity and surface roughness and elastic modulus, which should tend in its value to the elastic modulus of bone tissue that is $E = 20$ GPa (at $H = 1.2$ GPa) [15]. In our opinion, the elastic modulus should be considered in osseointegration along with osteoconduction, since the subsidence effect observed by the use of implants made of titanium or high-strength plastic materials is directly related to the elastic modulus. This effect leads to the formation of angular kyphosis, and, consequently, to chronic pain.

Carbon implants along with high strength properties have osteoconductive properties that could provide the formation of a bone-to-carbon block due to the porous structure and elastic modulus, which is equal to $E = 20-30$ GPa for these implants, which is close enough to the elastic modulus of bone tissue (16-19). This fact is expressed in the absence of sagging of implants made of carbon in 38 out of 58 patients followed over a period of two years (65.51 % of cases). We observed the opposite in patients who underwent TMI implantation whose elastic modulus

was $E = 80$ GPa (at $H = 2.7$ GPa) [15], and implant subsidence was evident in all cases and differed only in degree (Table 6).

The formation of spinal fusion in group I, observed in 7 patients (12.07 % of cases) seems interesting from our morphological and biomechanical point of view: the osseointegration process manifested itself by filling the pores of the CCI with bone tissue, which can be considered as formation of bone-to-carbon block of varying degrees (Fig. 7).

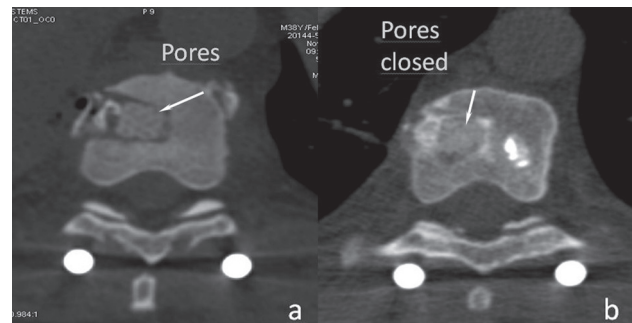


Fig. 7 Fracture of T5 vertebra, type A according to Denis. Resection of the vertebral body and interbody corporodesis with CCI and autobone from the resected rib: **a** implant pores are visible on the axial section after surgery; **b** implant pores are closed with bone tissue after 24 months, the peri-implant resorption zone is not seen: a bone-to-carbon block has been formed

CONCLUSION

Studies conducted by us with a 2-year follow-up period showed good and statistically significant results in the main and control groups. Despite the absence of bone-to-carbon conglomerate in a significant number of patients in the main group (86 % of cases), the results of the VAS scale and SF-36 questionnaires showed statistically comparable results with the group of patients in whom TMI was implanted and there was bone fusion between autologous bone and vertebral bodies (Fig. 6). We conclude that CCIs are inert, and

their use does not affect the physical condition and mental health of patients in the postoperative period. The absence of interference during the visualization of the spinal canal in the postoperative period enables to adequately assess the area of surgical intervention and the state of neural structures. Combination with autologous bone is necessary by use of CCI in spinal surgery. Future studies should be aimed at improving the osteoconductive properties of CCI by changing the design of the porous structure.

Conflict of interest: the authors did not receive funding for this work. There is no conflict of interest.

REFERENCES

1. Youssef J.A., McAfee P.C., Patty C.A., Raley E., DeBauche S., Shucosky E., Chotikul L. Minimally invasive surgery: lateral approach interbody fusion. *Spine*, 2010, vol. 35, no. 26 Suppl., pp. S302-S311. DOI: 10.1097/BRS.0b013e3182023438.
2. Heary R.F., Schlenk R.P., Sacchieri T.A., Barone D., Brotea C. Persistent iliac crest donor site pain: independent outcome assessment. *Neurosurgery*, 2002, vol. 50, no. 3, pp. 510-516. DOI: 10.1097/00006123-200203000-00015.
3. Silber J.S., Anderson D.G., Daffner S.D., Brislin B.T., Leland J.M., Hilibrand A.S., Vaccaro A.R., Albert T.J. Donor site morbidity after anterior iliac crest bone harvest for single-level anterior cervical discectomy and fusion. *Spine*, 2003, vol. 28, no. 2, pp. 134-139. DOI: 10.1097/01.BRS.0000041587.55176.67.

4. Sasso R.C., LeHuec J.C., Shaffrey C.; Spine Interbody Research Group. Iliac crest bone graft donor site pain after anterior lumbar interbody fusion: a prospective patient satisfaction outcome assessment. *J. Spinal Disord. Tech.*, 2005, vol. 18 Suppl., pp. S77-S81.
5. Försth P., Ölafsson G., Carlsson T., Frost A., Borgström F., Fritzell P., Öhagen P., Michaëlsson K., Sandén B. A Randomized, Controlled Trial of Fusion Surgery for Lumbar Spinal Stenosis. *N. Engl. J. Med.*, 2016, vol. 374, no. 15, pp. 1413-1423. DOI: 10.1056/NEJMoa1513721.
6. Osintsev V.V., Osintsev V.M., Durov M.F. *Preimushchestva perednego spondilodeza poristym nikelidom titana pri povrezhdeniakh sheinogo otdela pozvonochnika* [The advantages of anterior spondylodesis with porous titanium nickelide for injuries of the cervical spine]. *Aktualnye Voprosy Implantologii i Osteosinteza*. Sb. nauch. tr. [Abstracts "Current Problems of Implantology and Osteosynthesis"]. Novokuznetsk, 2000. P. 79-83. (in Russian)
7. Shalamov A.M., Lavrukov A.M., Zhuravlev A.A. O novom podkhode k lecheniiu tuberkuleznogo spondilita [On a new approach to treating tuberculous spondylitis]. "Vysokie Tekhnologii v Travmatologii i Ortopedii: organizatsiia, diagnostika, lechenie, reabilitatsiia, obrazovanie". *Tez. dokl. I sezda travmatologov-ortopedov Uralskogo Federal. Okruga* [Proc. 1st Congress of traumatologists-orthopedists of the Ural Federal District "High Technologies in Traumatology and Orthopaedics: organization, diagnosing, treatment, rehabilitation, education"]. Ekaterinburg, 2005, pp. 178-179. (in Russian)
8. Hodgson A.R., Stock F.E. The Classic: Anterior spinal fusion: a preliminary communication on the radical treatment of Pott's disease and Pott's paraplegia 1956. *Clin. Orthop. Relat. Res.*, 2006, vol. 444, pp. 10-15. DOI: 10.1097/01.blo.0000203456.67016.b7.
9. D'Ambrosia R.D. Precision Medicine: A New Frontier in Spine Surgery. *Orthopedics*, 2016, vol. 39, no. 2, pp. 75-76. DOI: 10.3928/01477447-20160304-03.
10. Zaratsian A.K., Lavrishcheva G.I. Obosnovanie primeniia ugleplastika UPA-12 v meditsine [Substantiation of applying UPA-12 carbon plastic in medicine]. *Vtoraia Konferentsiia po probleme fiziko-khimicheskoi biologii i biotekhnologii v meditsine*. *Tez. dokl.* [Proc. 2nd Conference on the Problem of Physicochemical Biology and Biotechnology in Medicine]. Erevan, 1986, pp. 31. (in Russian)
11. Kostikov V.I., Iumashev G.S., Lopatto Iu.S. *Tezisy dokladov 5-i Vsesoiuznoi Konferentsii po kompozitsionnym materialam* [Proc. V All-Union Conference on composite materials]. M., Izd-vo MGU, 1981, ed. 2, pp. 210-211. (in Russian)
12. Iumashev G.S., Lavrov I.N., Kostikov V.I., Lopatto Iu.S., Miaskovskaia S.P. Primenenie uglerodnykh materialov v meditsine (obzor literatury) [Use of carbon materials in medicine (Review of the literature)]. *Ortopediia, Travmatologiya i Protezirovaniye*, 1983, no. 5, pp. 62-64. (in Russian)
13. Iumashev G.S., Lavrov I.N., Kostikov V.I., Kulikov L.S., Kriukov B.N., Khurtsilava N.D., Iumashev A.G., Gumnitskii M.B. Zameshchenie kraevykh defektov kosti uglerodnymi implantatami [Replacement of marginal bone defects with carbon implants]. *Vestnik Khirurgii*, 1986, vol. 138, no. 3, pp. 93-95. (in Russian)
14. Becker D. Unusual application of carbon fiber ligaments to joints. *Unfallheilkunde*, 1984, vol. 87, no. 4, pp. 163-167.
15. Bokros J.C. Carbon biomedical devices. *Carbon*, 1977, vol. 15, no. 6, pp. 355-371.
16. Gupta A., Kukkar N., Sharif K., Main B.J., Albers C.E., El-Amin Iii S.F. Bone graft substitutes for spine fusion: A brief review. *World J. Orthop.*, 2015, vol. 6, no. 6, pp. 449-456. DOI: 10.5312/wjo.v6.i6.449.
17. Zaratsian A.K., comp. *Primenenie uglerodnykh konstruktsii v travmatologii i ortopedii: metod. rekomendatsii* [Use of carbon structures in traumatology and orthopaedics: a technique manual]. Erevan, 1988. (in Russian)
18. Gnedonov S.V., Sharkeev Iu.P., Sinebriukhov S.L., Khrisanova O.A., Legostaeva E.V., Zavidnaia A.G., Puz A.V., Khlusov I.A. Funktsionalnye pokrytiia dlia implantatsionnykh materialov [Functional coatings for implantation materials]. *Tikhookeanskii Meditsinskii Zhurnal*, 2012, no. 1, pp. 12-19. (in Russian)
19. Skriabin V.L. Zameshchenie defektov gubchatoi kosti iskusstvennymi materialami (obzor literatury) [Replacement of spongy bone defects with artificial materials (A review of the literature)]. *Permskii Meditsinskii Zhurnal*, 2008, vol. 25, no. 2, pp. 115-122. (in Russian)

Received: 24.05.2019

Information about authors:

1. Sergei V. Kolesov, M.D., Ph.D.,
National Medical Research Center of Traumatology and Orthopedics n.a. N.N. Priorov, Moscow, Russian Federation
2. Dmitrii A. Kolbovskii, M.D.,
Russian Medical Academy of Continuing Professional Education, Moscow, Russian Federation;
Email: dr.kolbovskiy@yandex.ru
3. Vladimir V. Shvets, M.D., Ph.D.,
National Medical Research Center of Traumatology and Orthopedics n.a. N.N. Priorov, Moscow, Russian Federation
4. Viktor V. Rerikh, M.D., Ph.D.,
Novosibirsk Research Institute of Traumatology and Orthopaedics N.a. Ya.I. Tsivyan, Novosibirsk, Russian Federation
5. Arkadii A. Vishnevskii, M.D., Ph.D.,
St. Petersburg Research Institute of Phthisiopulmonology, Saint Petersburg, Russian Federation
6. Nataliia S. Morozova, M.D.,
National Medical Research Center of Traumatology and Orthopedics n.a. N.N. Priorov, Moscow, Russian Federation
7. Igor V. Skorina, M.D.,
National Medical Research Center of Traumatology and Orthopedics n.a. N.N. Priorov, Moscow, Russian Federation
8. Dmitrii S. Gorbatiuk, M.D.,
National Medical Research Center of Traumatology and Orthopedics n.a. N.N. Priorov, Moscow, Russian Federation